Global Revascularization

J. Stephen Jenkins, MD, FACC, Tyrone J. Collins, MD, FACC, Stephen R. Ramee, MD, FACC, Christopher J. White, MD, FACC

Department of Cardiology, Ochsner Clinic and Alton Ochsner Medical Foundation, New Orleans, LA

Percutaneous endovascular intervention has revolutionized the treatment of peripheral vascular disease by allowing successful treatment of patients who are not good surgical candidates. Cardiologists with peripheral vascular training are more readily able to identify patients with concomitant peripheral arterial disease. It has been our experience that the technical skills necessary to perform coronary angioplasty are transferable to the peripheral vasculature. However, an understanding of the natural history of peripheral disease and of patient and lesion selection criteria, and the knowledge of other treatment alternatives are essential elements required to perform these procedures safely and effectively. There are inherent advantages for patients when the interventionalist performing the procedure is also the clinician responsible for the pre- and post-procedure care, analogous to the vascular surgeon who cares for patients before and after surgical procedures. In view of the increased incidence of coronary artery disease in patients with atherosclerotic peripheral vascular disease, the participation of a cardiologist in their care seems appropriate.

Jenkins JS, Collins TJ, Ramee SR, White CJ. Global revascularization. The Ochsner Journal 2001;3:70-77.

Since Dotter and Judkins performed the first iliac artery angioplasty with a coaxial catheter system in 1964, percutaneous endovascular intervention has revolutionized the treatment of peripheral vascular disease (1,2). Gruentzig introduced percutaneous transluminal balloon angioplasty in the late 1970s and popularized the technique now termed angioplasty. In 1987, Sigwart performed the first successful metallic stent implantation in the human peripheral vasculature (3).

Since the earliest days, percutaneous endovascular therapy has allowed successful treatment of peripheral vascular disease in patients who were not good surgical candidates. As the field of endovascular intervention has grown, a number of disciplines including vascular surgery, cardiology, and interventional radiology have begun to treat this diffuse disease that plagues our society.

Due to the diffuse nature of atherosclerotic disease, a systemic disorder that affects not only the coronary vasculature but the peripheral vasculature as well, the cardiologist may be the first specialist to see the patients with peripheral vascular disease. Cardiologists with peripheral vascular training more readily identify patients with concomitant peripheral arterial disease, and there are compelling reasons for cardiologists to undertake a more global approach to the patient with atherosclerotic coronary artery disease. Coronary artery disease (CAD) is the most common cause of morbidity and mortality in patients with atherosclerotic peripheral vascular disease. Peripheral vascular symptoms such as claudication impair the effectiveness of cardiovascular rehabilitation programs and renal artery stenosis causing resistant hypertension, which negatively impacts the management of angina pectoris and congestive heart failure.

When assessing patients with peripheral vascular occlusive disease, it is important to remember that there is a significant incidence of CAD, which is the major cause of mortality in these patients. Appropriate assessment of these patients includes a carotid, abdominal, and lower extremity vascular examination as well as appropriate screening and assessment for CAD. A noninvasive cardiac stress test is generally appropriate to assess the risk of suspected CAD in a patient with atherosclerotic peripheral vascular disease. Endovascular intervention allows physicians to treat patients with severe disabling peripheral vascular disease using highly successful and safe techniques that have durable results.

Carotid Artery Stenting

Stroke is the third leading cause of death and the leading cause of disability among adults in the United States (4). Several

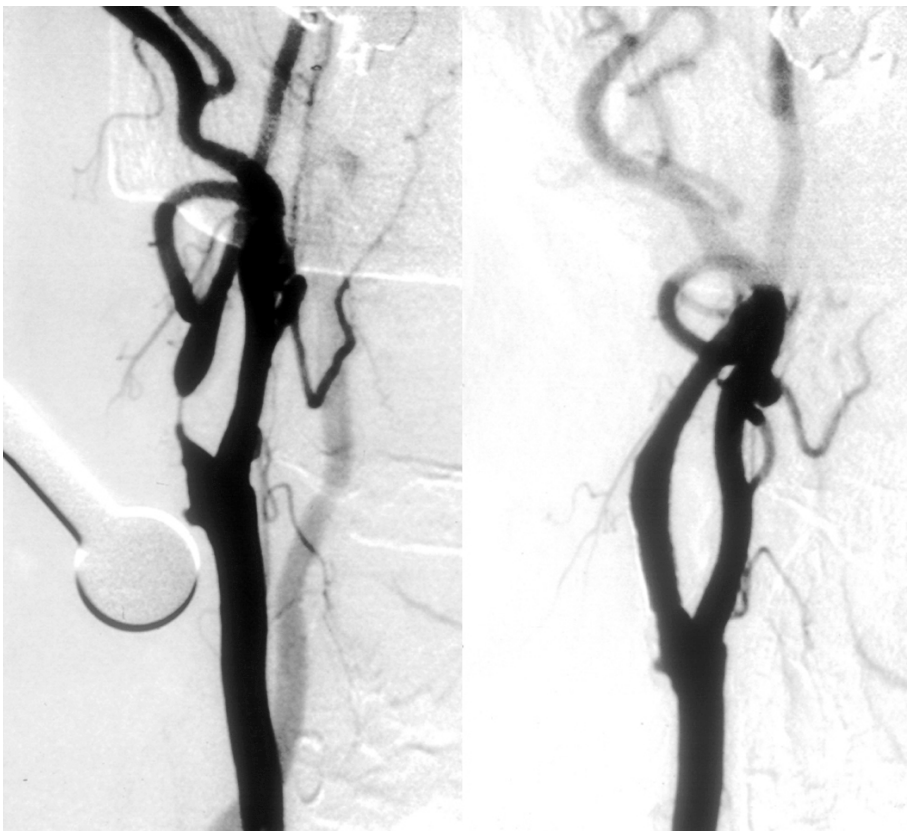

Figure 1. Critical stenosis of the internal carotid artery shown before and after balloon angioplasty and stenting with a self-expanding stent.

randomized clinical trials have demonstrated the superiority of carotid endarterectomy over the best medical therapy in the treatment of symptomatic and asymptomatic high-grade carotid artery stenosis. Surgery, however, has its own limitations and risks. For symptomatic carotid stenosis, the North American Symptomatic Carotid Endarterectomy Trial (NASCET) has reported all perioperative stroke and death rate combined at 5.8%, and the major stroke and death rate at 2.1% (5). In this study, carotid endarterectomy was found significantly beneficial compared with medical therapy when all strokes and deaths were included in the analysis. For asymptomatic carotid stenosis, the Executive Committee for the Asymptomatic Carotid Atherosclerosis (ACAS) investigators reported an all stroke/death rate of 2.3% at 30 days, and 5.1% at 5 years for the surgical cohort (6).

Recently, carotid artery stenting has emerged as an alternative treatment for stroke prevention in selected patients. In 1998, Wholey et al (7) compiled survey responses from 2048 carotid stent placements in 24 major centers including Ochsner. More than 60% of these procedures were performed by cardiologists. A large proportion of these patients would have been excluded from the NASCET and ACAS clinical trials. The centers reported a technical success rate of 98.6%, with a major stroke rate of 1.32%, a minor stroke rate of 3.08%, and a mortality rate of 1.37% at 30 days.

Most recently, Wholey et al (8) updated the carotid stent survey in these 24 centers and added 12 new centers. The total number of endovascular carotid stent procedures that have been performed worldwide in these 36 major centers to date includes 5210 procedures involving 4757 patients. There was a technical success of 98.4% with 5129 carotid arteries treated. Complications that occurred during the carotid stent placement or within 30 days were reported. The centers reported a major stroke rate of 1.49%, minor stroke rate of 2.72%, transient ischemic attack rate of 2.82%, and mortality rate of 0.86%. The combined major and minor stroke and procedure-related death rate was 5.07%. The rate of neurologic events after stent placement was 1.42% at 6- to 12-month follow-up. Restenosis rates for carotid stenting have been 1.99% and 3.46% at 6 and 12 months, respectively.

In patients that are at high risk for carotid endarterectomy, endovascular stent placement for atherosclerotic CAD is growing as an alternative to vascular surgery. The periprocedural risks appear to be acceptable at this early stage of development of carotid stenting for treatment of atherosclerotic CAD in this high-risk population of patients (Figure 1).

Vertebral Artery Stenosis

Vertebrobasilar insufficiency due to posterior circulation ischemia is infrequent with the most likely culprit lesion location involving both vertebral arteries. Humans tolerate ligature of one of the two vertebral arteries well, making the clinical presentation of posterior ischemia symptoms infrequent. While bilateral vertebral artery disease is the most common cause, other combinations of innominate, subclavian, and carotid disease can compromise the posterior circulation. The syndrome of subclavian steal due to proximal stenosis of the subclavian or innominate artery can also produce posterior ischemic symptoms in patients with limited collateral flow. The initial management of these patients includes antiplatelet and anticoagulant therapy. If medical management fails to improve symptoms, aortic arch and four-vessel angiography with intracranial angiography is indicated.

Three surgical techniques have been described for vertebral artery reconstruction. Transection of the vertebral artery above the stenosis and reimplantation into the ipsilateral subclavian or carotid artery, vertebral artery endarterectomy, or vein patch angioplasty are the commonly used surgical techniques for treatment of this disease (9). Surgical revascularization is not without significant morbidity and mortality. Reported complications include: recurrent laryngeal nerve palsy, Horner's syndrome, lymphocele, chylothorax, and thrombosis (10).

Over the last 2 decades, percutaneous transluminal angioplasty (PTA) of the supra-aortic vessels has progressed from an experimental technique to an accepted treatment with results that equal or improve upon results of surgical treatment in aortic arch and brachiocephalic vessels. Vertebral disease has been less well studied due to the infrequency of true posterior circulation symptomatology and the lack of a safe and effective revascularization technique.

Only two series using stenting for treatment of atherosclerotic vertebral artery disease have been published. One of these studies was performed here at the Ochsner Heart and Vascular Institute by Jenkins et al (11) in 32 patients. The other, by Malek et al (12), included 13 vertebral and 8 subclavian arteries in the analysis. The latter reported 21 patients with both vertebral artery and subclavian artery lesions causing posterior circulation ischemia that were treated with stent supported balloon angioplasty. Thirteen vertebral artery and eight subclavian artery lesions were treated using self-expanding and balloon expandable stents. All procedures were successful. One hemispheric stroke (4.8%) and one transient ischemic attach (4.8%) occurred in this series.

Our group has successfully performed primary vertebral artery stent placement in 32 patients and 38 vertebral arteries (11). All but one patient had symptoms of vertebrobasilar insufficiency. Unilateral vertebral artery stenting was performed in 26 (81%) patients and bilateral stenting in 6 (19%) patients. Of the 38 lesions, 34 (90%) were located in the V_1 segment and 4 (10 %) lesions were located in the V_2 segment of the vertebral artery. A total of 42 stents were implanted including 10 balloon expandable biliary stents, 30 balloon expandable coronary stents, and 2 self-expanding coronary stents.

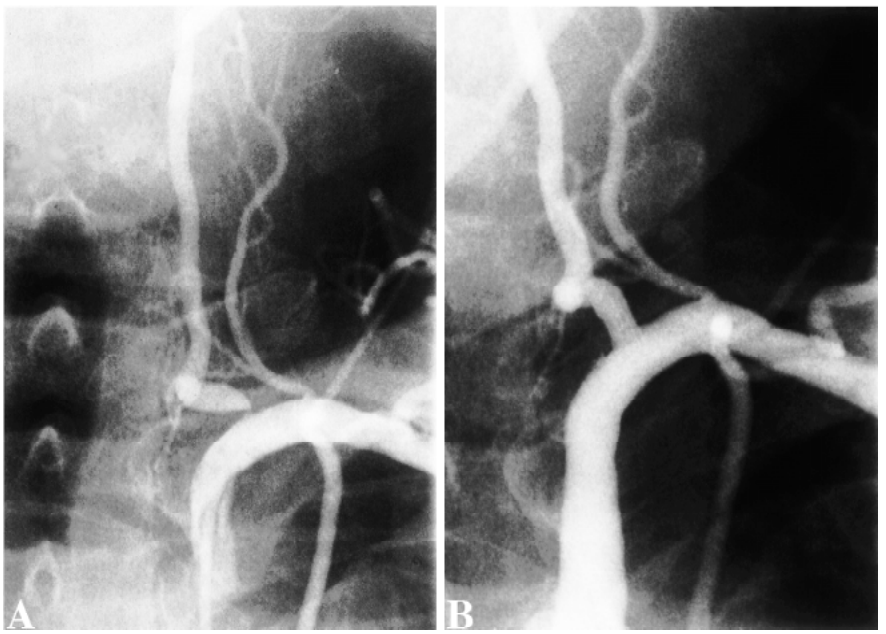

Figure 2. Left ostial vertebral artery with a 95% stenosis shown (A) before and (B) after stenting with a balloon expandable stent.

Indications for stenting were diplopia (n=4), blurred vision (n=4), dizziness (n=23), transient ischemic attacks (n=4), drop attack (n=1), gait disturbance (n=1), headache (n=2) and asymptomatic critical stenosis (n=1). Nine patients exhibited more than one symptom and one patient without symptoms had a critical stenosis of a solitary vertebral artery treated with stenting prior to coronary artery bypass grafting.

Procedural success was achieved in all 32 (100%) patients. One patient (3%) experienced a transient ischemic attack 1 hour following the procedure, which resolved within 5 minutes. Repeat angiography revealed a patent stent site without any focal spasm or occlusion of the intracranial arteries.

Clinical follow-up was available in all 32 patients at a mean of 10.6 months (range 1-37 months). One patient (3%) had recurrent dizziness at 3.5 months and was found to have in-stent restenosis, which was successfully treated with balloon angioplasty. The remaining 31 patients were asymptomatic at follow-up.

In conclusion, endoluminal stenting of vertebral artery lesions is safe, effective, and durable as evidenced by the low recurrence rate. Primary stent placement is an attractive option for atherosclerotic vertebral artery stenotic lesions (Figure 2).

Subclavian and Innominate Artery Stenosis

The first reported PTA of a brachiocephalic lesion was published by Bachman and Kim in 1980 (13). A tight left subclavian was successfully dilated to treat subclavian steal syndrome. Eleven-month follow-up demonstrated equal blood pressures in both arms with no recurrence of the baseline symptoms of left arm numbness or dizziness. PTA of the subclavian and innominate arteries both proximal and distal to the origin of the vertebral arteries is considered the treatment of choice for subclavian steal syndrome, upper extremity claudication, or preservation of internal mammary flow to the coronary circulation.

Surgical intervention has been effective; however, excessive perioperative morbidity/mortality has been reported using both transthoracic and extrathoracic revascularization for subclavian artery stenosis/occlusion. The perioperative morbidity/mortality using a direct transthoracic technique approaches 20% (14-16). In a series of 60 patients reported by Law et al, treatment of subclavian steal with carotid-subclavian bypass had a perioperative complication rate of 18.3% (17). Another series of carotid-subclavian bypass procedures in 109 patients over 20 years reported a perioperative morbidity and mortality rate of 6 % (18). These patients with diffuse vascular obstruction (particularly those with carotid disease) are poor candidates for bypass grafting. The morbidity and mortality (6%-18%) is related primarily to the coexistent coronary and cerebrovascular atherosclerotic obstructive disease.

The low incidence of embolic events following any intervention, including balloon angioplasty, may be explained by delayed restoration of antegrade vertebral flow. Ringlestein and Zeumer (19) have shown by continuous Doppler sonography that reversal of flow in the vertebral artery from retrograde to antegrade does not occur immediately after PTA but gradually over several minutes. This phenomenon theoretically protects the posterior fossa from embolization.

Results of PTA alone for brachiocephalic total occlusions have been poor and success rates lower than that for brachiocephalic stenoses. In one series of 80 patients, McNamara (20) reported a 74% success rate and a 12% recurrence rate at mean follow-up of

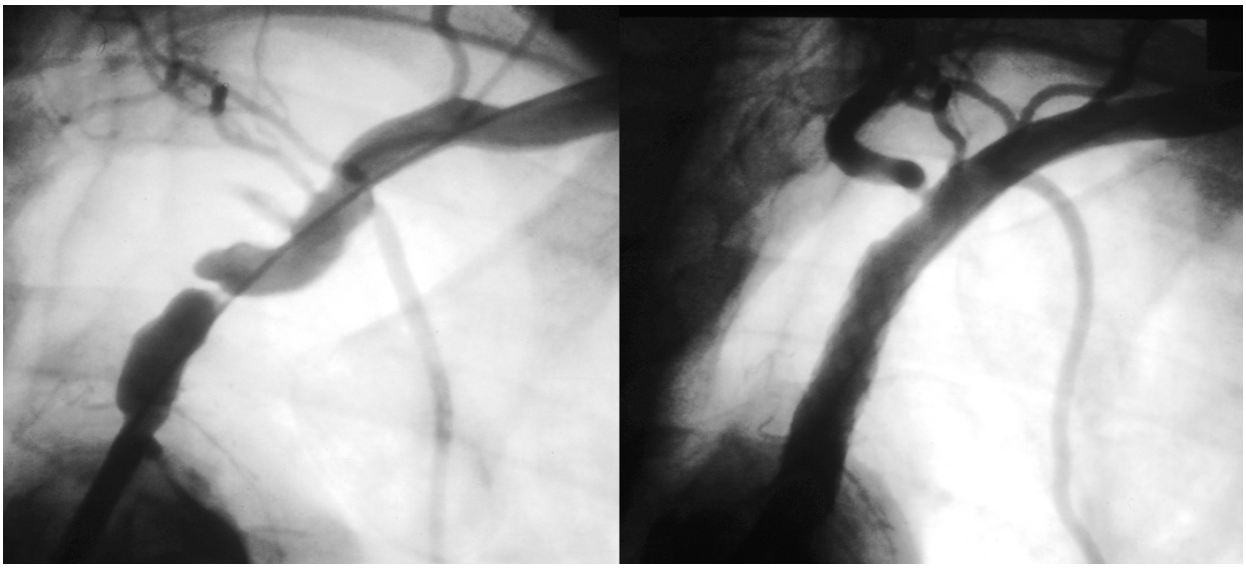

Figure 3. Left subclavian artery stenosis before and after stenting in a patient with a mammary artery to the heart.

33 months. In another series of 46 occlusions, Mathias et al (21) reported a success rate of 67% with restenosis/reocclusion rate of 19% at 33 month follow-up using PTA alone. Seven lesions in this series were stented for nonocclusive residual stenosis. The restenosis/reocclusion rate in the stented patients was 0% at 33-month follow-up.

Acute and long-term PTA results are much better for the treatment of supraclavicular stenoses. More than 1000 procedures to date have been published in the literature treating the subclavian, innominate, vertebral, and carotid arteries. Pooled data from 25 reports was recently reviewed by McNamara et al (20). A total of 992 stenoses were treated with PTA/stenting in 968 patients. The success rate was 95% with no deaths. Complication rates were low with a 0.3% incidence of arm emboli and a 0.4% incidence of stroke. Mean follow-up of 54 months was available for 457 patients with a restenosis rate of 5.7%.

We reviewed our results in 35 patients who underwent stenting for subclavian and innominate disease (22). Indications for stenting included arm claudication (n=21), subclavian steal (n=5), and compromised flow to an internal mammary artery bypass graft (n=9). Procedural success was defined as abolition of pressure gradient between the aorta and the subclavian artery and a residual diameter stenosis < 20% without major complications (acute stent thrombosis, myocardial infarction, embolization, emergency surgery, or death). Procedural success was achieved in all 35 patients (100%) and all had symptom relief. There were no major complications. At a mean follow-up of 2 years, 32 of 33 patients (97%) remained asymptomatic. One patient required repeat balloon angioplasty for restenosis 10 months after the procedure. Two (5.7%) patients died of congestive heart failure at 4 and 28 months after treatment. In summary, successful stenting of the subclavian and innominate artery can be achieved with high technical success and provides a durable clinical result (Figure 3).

Renal Artery Stenosis

Atherosclerotic renal artery stenosis, the most common cause of secondary hypertension, is present in about 4 % of the general population of hypertensive patients. In several clinical subsets of patients, however, atherosclerotic renal artery stenosis is much more common, such as those with hypertension and renal insufficiency, and in patients with associated coronary or peripheral vascular disease. In patients undergoing coronary angiography for suspected coronary artery disease, the incidence of renal artery stenosis ranges from 15% to 18%. In patients with known peripheral vascular disease, angiography demonstrated renal artery stenosis in 30% to 40% (23-25).

There is general agreement among investigators that the natural history of renal artery stenosis is to progress over time. The incidence of renal artery lesion progression in angiographic serial studies ranges from 39% to 49%. Many of these lesions progress to total occlusion and with the majority of these patients suffering loss of renal function manifested by increasing serum creatinine and decreasing renal size.

Clinical results with renal artery stent placement have documented superior hemodynamic and angiographic results compared with balloon angioplasty alone. Endovascular stenting enables a greater acute gain in lumen diameter than balloon angioplasty, largely defeating vascular recoil, thereby diminishing the impact of intimal hyperplasia on long-term patency.

We have recently reported our experience in 100 consecutive patients with renovascular hypertension and lesions difficult to treat with balloon angioplasty alone (26,27). A total of 149 stents were placed in 133 arteries of 100 consecutive patients with poorly controlled hypertension on medical therapy. Angiographic success was obtained in 99% (132/133) of arteries attempted. Clinical success, defined as normalization of the blood pressure on the same or fewer medications, was achieved in 76% of the patients at the 6-month clinic visit. One patient experienced a complication, stent thrombosis, 3 days post-procedure. There were no artery perforations or need for emergency surgery in any patient. Two patients experienced transient contrast nephropathy, which resolved without the need for dialysis.

At the 6-month follow-up, the improvement in blood pressure control continued to be statistically significant; the average number of antihypertensive medications per patient was reduced from 2.6 +/- 1.0 to 2.0 +/- 0.9 ($p < 0.001$), and the angiographic restenosis rate (> 50% diameter stenosis) was 18.8% (15/80) in the 67 patients undergoing follow-up angiography.

We have analyzed the results of renal artery stent placement in another group of 48 patients with unstable angina (n=23) or congestive heart failure (n=25) who had hypertension refractory to medical therapy and ≥ 70% stenosis of one (n=30) or both (n=18) renal arteries (28). For the entire cohort of patients, hypertension control was achieved within 24 hours in 87% and a sustained benefit was seen in 74% at 6 months.

In patients with significant renal artery stenosis presenting with unstable angina or congestive heart failure or both, renal artery stent implantation acutely improves symptoms due to favorable neurohormonal and hemodynamic effects. In patients with bilateral renal artery stenosis, renal artery stent revascularization allows the use of medical therapy, such as angiotensin-converting enzyme inhibitors, which would otherwise precipitate renal failure. A sustained clinical improvement in cardiac symptoms was seen in 73% of patients at a mean follow-up of 8.4 months in this study.

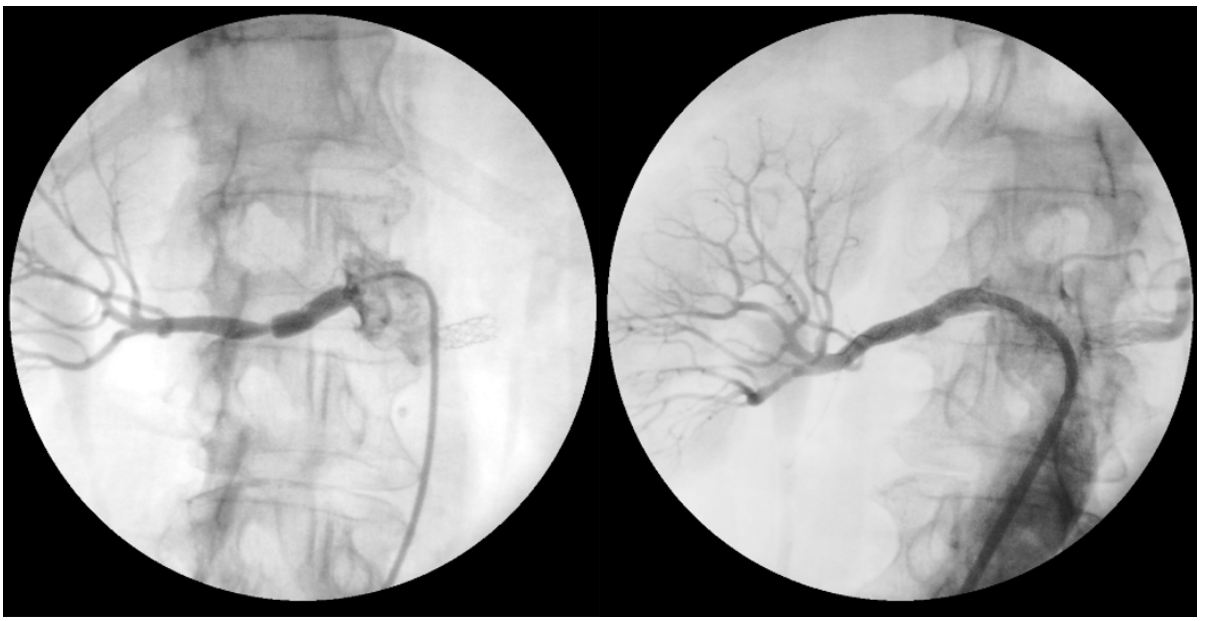

Figure 4. Right renal artery shown before and after balloon angioplasty and stenting.

A consensus is now developing that patients with renal artery stenosis and uncontrolled hypertension or renal insufficiency are appropriate candidates for revascularization. Patients on hemodialysis whose parenchyma is supplied by stenotic renal arteries and those with renal artery stenosis and refractory congestive heart failure or unstable angina may also be considered candidates for revascularization (Figure 4).

Aorto-Iliac Occlusive Disease

Patients with aorto-iliac occlusive disease may be asymptomatic or present with a range of symptoms from mild claudication to limb-threatening ischemia. The severity of symptoms will depend upon the severity of the stenosis, the presence of collateral circulation, and the presence of multilevel vascular disease. With isolated terminal aorta stenoses, generally both legs are equally affected, although disparities in collateral circulation or multilevel disease may render one limb more ischemic than the other.

The initial assessment should include a physical examination for signs of peripheral ischemia, distal embolization, and the status of the peripheral pulses. A rest and exercise ankle-brachial index (ABI) measurement should be performed. Commonly, a mild impairment in the resting ABI is dramatically exaggerated with exercise. Segmental ABIs with pulse volume recordings will indicate the presence or absence of multilevel occlusive disease. Another very helpful test in the pre-procedural assessment of these patients is the duplex (Doppler and ultrasound) examination. The duplex scan will provide information regarding the presence or absence of aneurysmal disease and indicate the severity of occlusive lesions. If there is doubt as to the presence of aneurismal disease, an abdominal contrast CT scan (ideally a spiral CT scan) should be performed.

The availability of endovascular stents has dramatically affected the results of balloon angioplasty of the iliac arteries. Due to the large diameter of the iliac vessels, the risk of thrombosis or restenosis after iliac placement of metallic stents is quite low. Stents may be placed "primarily" in an iliac lesion, without regard for the balloon angioplasty result, or they may be used "provisionally" in an iliac lesion following a suboptimal balloon angioplasty result. The two types of stents currently available, balloon-expandable (Palmaz; Johnson & Johnson Interventional Systems, Warren, NJ) and self-expanding (Wallstent; Schneider Stent, Plymouth, MN), have advantages and disadvantages. The balloon-expandable stents have greater radial force and allow greater precision for placement, which is particularly useful in ostial lesions. Self-expanding stents are more longitudinally flexible and can be delivered more easily from a contralateral femoral access site. The self-expanding stents also allow for normal vessel tapering and are particularly suited to longer lesions in which the proximal vessel may be several millimeters larger than the distal vessel.

The overall clinical benefit of iliac stent placement has been demonstrated using a meta-analysis of more than 2,000 patients from eight reported angioplasty (PTA) series and six stent series (29). The patients who received iliac stents had a statistically higher procedural success rate and a 43% reduction in late (4-year) failures than those treated with balloon angioplasty alone.

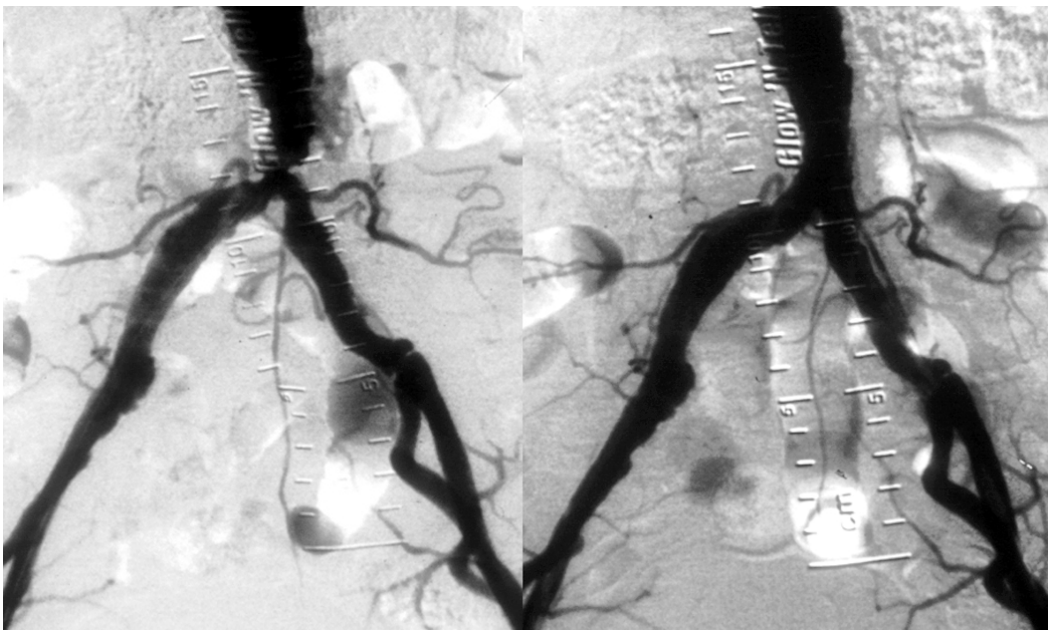

Figure 5. Percutaneous aortoiliac reconstruction using a kissing stent technique.

Placement of Palmaz balloon expandable stents has been evaluated in a multicenter trial (30) for iliac placement in 486 patients followed for up to 4 years (mean 13.3 +/- 11 months). Using life-table analysis, clinical benefit was present in 91% at 1 year, 84% at 2 years, and 69% of the patients at 43 months of follow-up. The angiographic patency rate of the iliac stents was 92%. Complications occurred in 10% and were predominantly related to the arterial access site. Five patients suffered thrombosis of the stent, of which four were recanalized with thrombolysis and balloon angioplasty. A report from a European randomized trial of primary iliac (Palmaz) stent placement versus balloon angioplasty demonstrated a 4-year patency of 92% for the stent group versus a 74% patency for the balloon angioplasty group (Figure 5).

Conclusion

It has been our experience that the technical skills necessary to perform coronary angioplasty are transferable to the peripheral vasculature. However, an understanding of the natural history of peripheral disease and of patient and lesion selection criteria, and the knowledge of other treatment alternatives are essential elements required to perform these procedures safely and effectively. For interventional cardiologists who are inexperienced in the treatment of peripheral vascular disease, appropriate preparation and training and a team approach including a vascular surgeon, interventional radiologist, or vascular specialist are desirable before attempting percutaneous peripheral angioplasty.

There are inherent advantages for patients when the interventionalist performing the procedure is also the clinician responsible for the pre- and post-procedure care, analogous to the vascular surgeon who cares for patients before and after surgical procedures. Judgments regarding the indications, timing, and risk-to-benefit ratio of procedures are enhanced by a long-term relationship between physician and patient. Finally, in view of the increased incidence of coronary artery disease and congestive heart failure in patients with atherosclerotic peripheral vascular disease, the participation of a cardiologist in their care seems appropriate.

References

1. Dotter CT, Judkins MP. Transluminal treatment of atherosclerotic obstruction: description of a new technic and a preliminary report of its application 1964. Radiology 1989;172:904-920.
2. Dotter CT. Transluminal angioplasty: a long view. Radiology 1980;135:561-564.
3. Sigwart U, Puel J, Mirkovitch V, et al. Intravascular stents to prevent occlusion and restenosis after transluminal angioplasty. N Engl J Med 1987;316:701-706.
4. Hurst RW. Carotid angioplasty. Radiology 1996;201:613-616.
5. Ferguson GG, Eliasziw M, Barr HW, et al. The North American Symptomatic Carotid Endarterectomy Trial: surgical results in 1415 patients. Stroke 1999; 30:1751-1758.
6. Endarterectomy for asymptomatic carotid artery stenosis. Executive Committee for the Asymptomatic Carotid Atherosclerosis Study. JAMA 1995; 273:1421-1428.

7. Wholey MH, Wholey M, Bergeron P, et al. Current global status of carotid artery stent placement. Cathet Cardiovasc Diagn 1998; 44:1-6.
8. Wholey MH, Wholey M, Mathias K, et al. Global experience in cervical carotid artery stent placement. Catheter Cardiovasc Interv 2000; 50:160-167.
9. Molnar RG, Naslund TC. Vertebral artery surgery. Surg Clin North Am 1998; 78:901-913
10. Berguer R. Long-term results of vertebral artery reconstruction. In: Yao JST, Pearce WH (editors). Long-term Results in Vascular Surgery. Norwalk, CT: Appleton & Lange, 1993, p 69.
11. Jenkins JS, White CJ, Ramee SR, et al. Vertebral insufficiency: When to intervene and how? Curr Interv Cardiol Rep 2000; 2:91-94.
12. Malek AM, Higashida RT, Phatouros CC, et al. Treatment of posterior circulation ischemia with extracranial percutaneous balloon angioplasty and stent placement. Stroke 1999; 30:2073-2085.
13. Bachman DM, Kim RM. Transluminal dilatation for subclavian steal syndrome. AJR Am J Roentgenol 1980; 135:995-996.
14. Crawford ES, De Bakey ME, Morris GC Jr, et al. Surgical treatment of occlusion of the innominate, common carotid, and subclavian arteries: a 10 year experience. Surgery 1969; 65:17-31.
15. Raithel D. Our experience of surgery for innominate and subclavian lesions. J Cardiovasc Surg (Torino) 1980; 21:423-430.
16. Fields WS, Lemak NA. Joint study of extracranial arterial occlusion. VII. Subclavian steal—a review of 168 cases. JAMA 1972; 222:1139-1143.
17. Law MM, Colburn MD, Moore WS, et al. Carotid-subclavian bypass for brachiocephalic occlusive disease. Choice of conduit and long-term follow-up. Stroke 1995; 26: 1565-1571.
18. AbuRahma AF, Robinson PA, Jennings TG. Carotid-subclavian bypass grafting with polytetrafluoroehtylene grafts for symptomatic subclavian artery stenosis or occlusion: A 20-year experience. J Vasc Surg 2000;32:411-418.
19. Ringelstein EB, Zeumer H. Delayed reversal of vertebral artery flow following percutaneous transluminal angioplasty for subclavian steal syndrome. Neuroradiology 1984; 26:189-198.
20. McNamara TO, Greaser LE III, Fischer JR, et al. Initial and long term results of treatment of brachiocephalic arterial stenoses and occlusions with balloon angioplasty, thrombolysis, stents. J Invasive Cardiol 1997; 9:372-383.
21. Mathias KD, Luth I, Haarmann P. Percutaneous transluminal angioplasty of proximal subclavian artery occlusions. Cardiovasc Intervent Radiol 1993; 16:214-218.
22. Jain SP, Zhang SY, Khosla S, et al. Subclavian and innominate arteries stenting: acute and long term results. J Am Coll Cardiol 1998; 31:63A .
23. Swartbol P, Thorvinger BOT, Parsson H, et al. Renal artery stenosis in patients with peripheral vascular disease and its correlation to hypertension. A retrospective study. Int Angiol 1992; 11:195-199.
24. Olin JW, Melia M, Young JR, et al. Prevalence of atherosclerotic renal artery stenosis in patients with atherosclerosis elsewhere. Am J Med1990; 88 (Supp IN):46N-51N.
25. Choudhri AH, Cleland JGF, Rowlands PC. Unsuspected renal artery stenosis in peripheral vascular disease. BMJ 1990: 301:1197-1198.
26. White CJ, Ramee SR, Collins TJ, et al. Renal artery stent placement: utility in lesions difficult to treat with balloon angioplasty. J Am Coll Cardiol 1997; 30:1445-1450.
27. White CJ, Ramee SR, Collins TJ, et al. Renal artery stent placement: indications, techniques and clinical results. Indian Heart J 1990; 50 Suppl 1:153-160.
28. Khosla S, White CJ, Collins TJ, et al. Effects of renal artery stent implantation in patients with renovascular hypertension presenting with unstable angina or congestive heart failure. Am J Cardiol 1997; 80:363-366.
29. Bosch JL, Hunink MG. Meta-analysis of the results of percutaneous transluminal angioplasty and stent placement for aortoiliac occlusive disease. Radiology 1997; 204:87-96.
30. Palmaz JC, Laborde JC, Rivera FJ, et al. Stenting of the iliac arteries with the Palmaz stent: experience from a multicenter trial. Cardiovasc Intervent Radiol 1992; 15:291-297.

Dr. Jenkins is on staff in Ochsner's Department of Cardiology.