

Ochsner Journal xx:1-4, xxxx
© Academic Division of Ochsner Clinic Foundation
DOI: 10.31486/toj.17.0111

Extensive Abdominal Sarcoidosis Without Pulmonary Manifestation

Abdulaziz Alatmi, MD,¹ Abdulaziz U. Joury, MD,^{2,3} Abeer Mubarak, MD¹

¹Department of Internal Medicine, Prince Sultan Military Medical City, Riyadh, Saudi Arabia ²King Salman Heart Center, King Fahad Medical City, Riyadh, Saudi Arabia ³Department of Internal Medicine, Ochsner Clinic Foundation, New Orleans, LA

Background: Sarcoidosis is a rare multisystem disease of idiopathic etiology that affects different organs and is characterized histopathologically by the presence of noncaseating granulomas. The most common location of sarcoidosis is the lungs, accounting for approximately 95% of sarcoidosis cases. Coincident involvement of pulmonary and extrapulmonary organs is present in approximately one-third of patients. However, the sole involvement of intraabdominal organs is extremely rare. Intraabdominal sarcoidosis has a different presentation depending on the involved organs. To the best of our knowledge, a limited number of case reports have been published on intraabdominal sarcoidosis without pulmonary involvement.

Case Report: A 69-year-old female patient presented with short onset of abdominal pain and change in bowel habits, without a significant medical history of abdominal problems. Physical examination only revealed generalized abdominal tenderness on deep palpation. Computed tomography of the abdomen and pelvis showed mild to moderate thickening of the omentum and other abdominal organs. After excluding various etiologies such as fungi and acid-fast bacilli, the omentum, ovaries, and surrounding lymph nodes were removed via a laparoscopic procedure. The histopathology report confirmed the diagnosis of intraabdominal sarcoidosis with the presence of noncaseating granulomas.

Conclusion: Extrapulmonary sarcoidosis is a rare disease, and intraabdominal sarcoidosis might mimic other malignant etiologies. We treated our case with laparoscopic removal of involved organs and oral steroids with significant recovery during a short period.

Keywords: *Granuloma, lymphoproliferative disorders, rare diseases, sarcoidosis*

Address correspondence to Abdulaziz Alatmi, MD, Department of Internal Medicine, Prince Sultan Military Medical City, As Sulimaniyah, Riyadh 12233, Saudi Arabia. Tel: +966-11-477-7714. Email: aziz.atmi@hotmail.com

INTRODUCTION

Sarcoidosis is a rare multisystem disease of idiopathic etiology with an incidence ranging from 1-40 per 100,000 cases and the hallmark histologic feature of noncaseating granulomas.¹⁻³ Sarcoidosis most commonly affects the lungs, accounting for approximately 95% of cases, followed by involvement of the skin and lymph nodes.¹⁻⁴ The most common sites of extrapulmonary sarcoidosis are the reticuloendothelial system, ocular structures, and musculoskeletal structures, and involvement of the reticuloendothelial system is present in almost one-third of patients with sarcoidosis.²⁻⁵ The characteristics of sarcoidosis vary depending on organ involvement, and the symptoms at presentation vary according to the sex of the patient. Female patients tend to have skin or eye involvement, whereas male patients more commonly present with cardiac sarcoidosis.^{2,6}

Intraabdominal sarcoidosis without pulmonary involvement is extremely rare; studies have shown that isolated intraabdominal sarcoidosis represents only approximately 10% of sarcoidosis cases.^{7,8} In most of these cases, the iso-

lated extrapulmonary sarcoidosis was confined to one or two organs such as the spleen alone,⁷ the accessory spleen in the greater omentum,⁸ or the liver and spleen.⁹

We report the case of a 69-year-old female who presented with abdominal pain and changes in bowel habits and who was diagnosed with intraabdominal sarcoidosis. To the best of our knowledge, no previous report shows such extensive intraabdominal sarcoidosis in the absence of pulmonary involvement.

CASE REPORT

A 69-year-old female with no known previous chronic disease presented to the outpatient clinic with complaints of an 8-month history of abdominal pain and distention. Her pain started in the periumbilical area and then generalized to her abdomen. She described the pain as constipation and reported that since the symptoms started, she had had less frequent bowel movements than before. Her abdominal pain, distention, and constipation were progressive for a period of months, causing her to seek medical advice. She

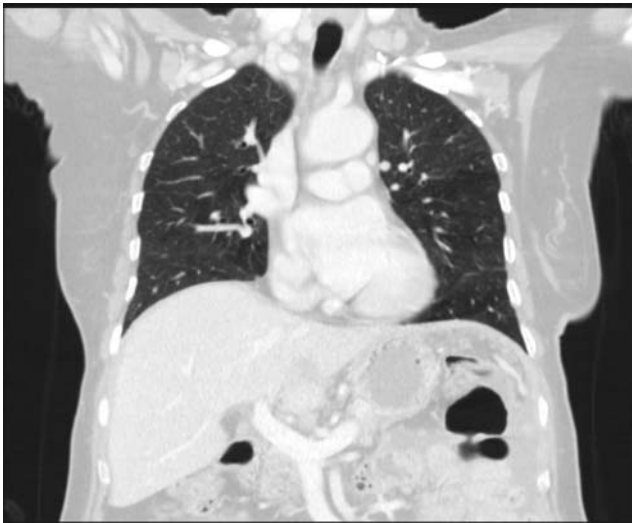

Figure 1. Coronal contrast-enhanced chest computed tomography scan shows no mediastinal lymph nodes, no evidence of metastatic disease, and no significant pulmonary finding except mild basal bronchial thickening.

took laxatives and acetaminophen to alleviate her constipation and abdominal pain; she took no other medications. Her appetite decreased, and she lost approximately 44 pounds in 3 months. She had no history of abdominal surgery except cesarean section more than 20 years prior. She had no known allergies, and her occupational and family histories were noncontributory.

Her vital signs were stable; cardiovascular and lung examinations were normal. The patient's abdomen, however, was distended with a clear outward expansion of her waist. Mild tenderness was provoked on deep palpation, and a firm mass underlying most areas of her abdomen was noted. No guarding or rebound tenderness was noticed; bowel sounds were absent. Digital rectal examination showed intact anal sphincter and no hemorrhoids or blood per rectum.

Laboratory investigations showed a normal white blood count, slight normocytic normochromic anemia with hemoglobin of 11.3 g/dL (reference range, 12.0-15.5 g/dL for females), and normal platelets. Comprehensive metabolic panel parameters were within normal limits. Alpha-fetoprotein, antinuclear antibodies, anti-smooth muscle antibody, and anti-ribonucleoprotein antibodies were negative. The patient's only significant elevation was an anti-cancer antigen 125 value of 218 kU/L (reference range, 0-35 kU/L).

Chest x-ray was normal. Pelvic ultrasound showed moderate ascites and an endometrial cyst that measured 3.8 mm. Chest computed tomography (CT) showed no mediastinal lymph nodes and no significant pulmonary finding except mild basal bronchial thickening (Figure 1). Abdominal and pelvic CT showed significant omental caking and thickening with evidence of multiple lymph node enlargement and evidence of significant ascitic fluid (Figures 2 and 3).

A laparoscopic procedure revealed an extensive intraabdominal mass that resembled a carcinomatous mass. The patient underwent complete resection of the greater omentum, a large portion of her small intestine, and her ovaries and fallopian tubes. Her initial abdominal pain was attributed to this extensive involvement of different intraabdominal

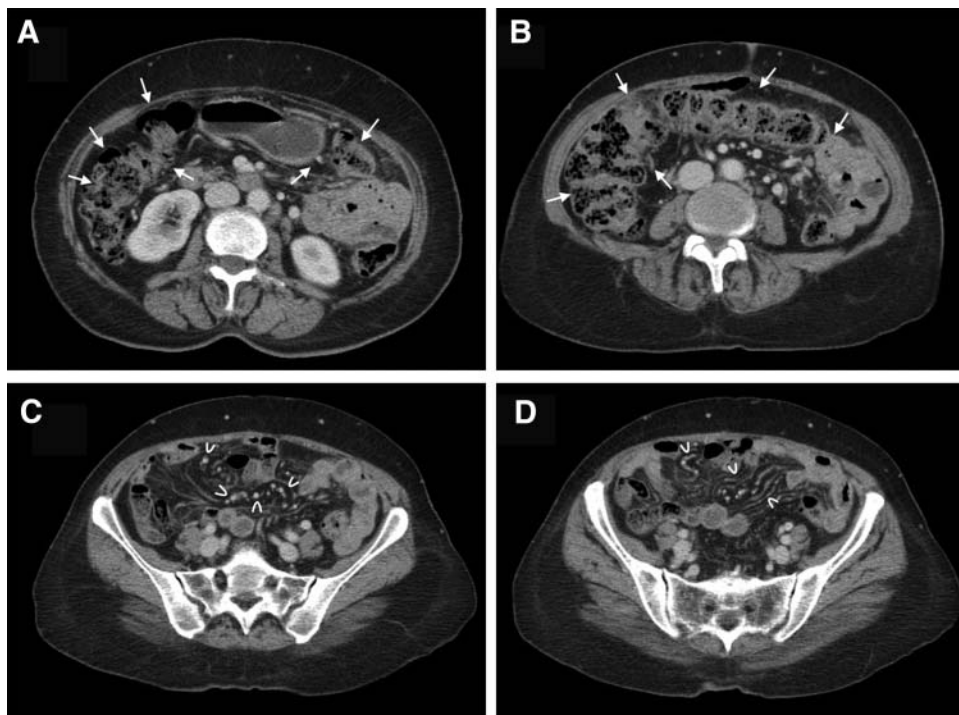


Figure 2. Contrast-enhanced abdominal and pelvis computed tomography scans in the axial plane show intestinal thickening and significant stool impaction (A, B, arrows) secondary to mechanical obstruction from fibrosis and thickening of sarcoidosis that involved the greater omentum (C, D, curved arrowheads) and other abdominal organs.

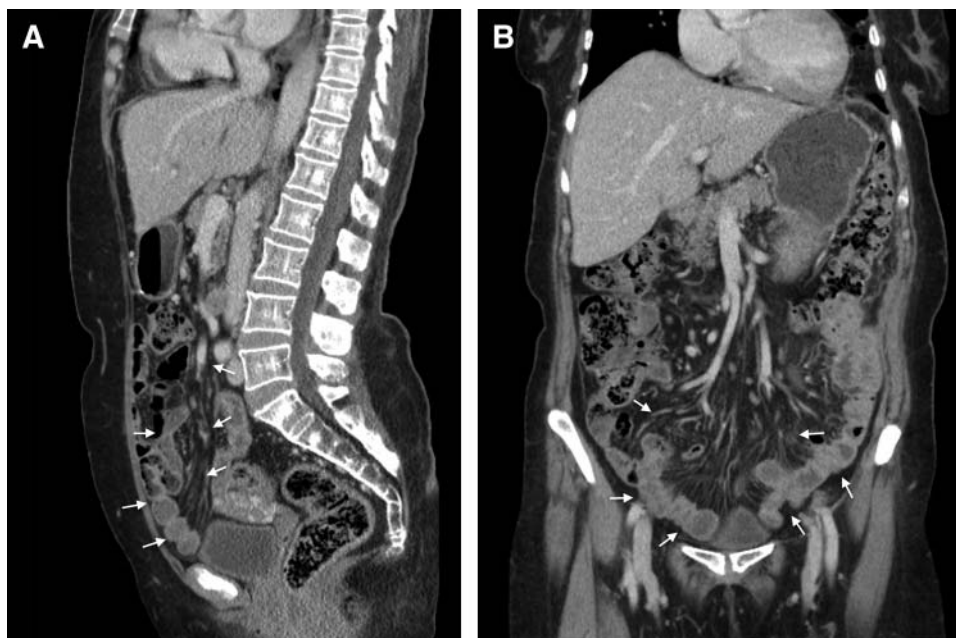

Figure 3. Sagittal (A) and coronal (B) views of an abdominal and pelvis computed tomography scan show thickening of the abdominal organs, specifically of the greater omentum (arrows). Surgical resection of the greater omentum revealed chronic granulomatous inflammation, confirming the diagnosis of gastrointestinal sarcoidosis.

organs. The patient recovered from surgery with no complications.

Histopathology of the fallopian tubes and peritoneum showed numerous epithelioid tissues and well-formed non-caseating granulomas. Grocott methenamine silver stain, periodic acid–Schiff stain, and acid-fast bacilli smear and stain were negative. Fluid cytology revealed numerous neutrophils, lymphocytes, and histiocytes and a few eosinophils consistent with inflammatory process, with no evidence of malignant cells. These analyses confirmed the diagnosis of sarcoidosis.

After surgery, the patient was started on prednisone 60 mg orally for 2 weeks with the plan to taper the steroids by 10 mg every 2 weeks and to monitor her symptoms. She completely tapered the steroids with no symptoms or signs of sarcoidosis flare. At follow-up, the patient showed significant improvement in her obstructive symptoms and overall quality of life.

DISCUSSION

Extrapulmonary sarcoidosis is a relatively rare presentation that most commonly affects the skin, lymph nodes, or reticuloendothelial organs.¹⁻⁴ Certain demographic characteristics are associated with certain organ involvement such as the liver, spleen, or lymph nodes.^{2,6} Symptoms of sarcoidosis are associated with the involved organs and include shortness of breath and cough with pulmonary involvement and portal hypertension manifestation with liver sarcoidosis.¹⁰⁻¹² Our patient presented with chronic abdominal pain and distention, and her chronic constipation was concerning for possible functional bowel disease or chronic mechanical obstruction.

Different imaging modalities were important to her work-up. Her chest x-ray was normal, but chest x-ray is limited

in its ability to differentiate between pulmonary and intrathoracic pathologies.¹⁰ CT scan is considered a more sensitive test in the setting of symptoms associated with involved organs such as the portal hypertension complication with liver sarcoidosis.⁷⁻¹¹

The clinical presentation of abdominal sarcoidosis is not specific and generally mimics other abdominal diagnoses such as small bowel obstruction or other obstructive pathology. Having such extensive disease of the gastrointestinal tract and surrounding organs without involvement of mediastinal structures is extremely rare. A previous case report showed extensive involvement of the gastrointestinal tract with atypical pulmonary features revealed by chest imaging.¹³

Abdominal sarcoidosis is treated differently than intrathoracic sarcoidosis, and treatment is determined by the severity of symptoms, organ involvement, and surgical candidacy. Some patients with isolated organ involvement such as the spleen or parts of the greater omentum have been treated surgically.⁸ Extensive involvement of other abdominal organs without the presence of intestinal obstructive symptoms is usually treated with systemic steroids.⁹ We treated our patient with surgical removal to alleviate the obstruction and confirm the diagnosis, followed by systemic steroids for a short period.

CONCLUSION

Extrapulmonary sarcoidosis is relatively rare, and the most common organs affected are the reticuloendothelial system and lymph nodes. In most previous case reports, the sarcoidosis is localized to a limited number of organs. Our patient had extensive sarcoidosis that involved multiple intraabdominal organs without pulmonary or mediastinal involvement.

ACKNOWLEDGMENTS

The authors have no financial or proprietary interest in the subject matter of this article.

REFERENCES

1. Baughman RP, Teirstein AS, Judson MA, et al; Case Control Etiologic Study of Sarcoidosis (ACCESS) research group. Clinical characteristics of patients in a case control study of sarcoidosis. *Am J Respir Crit Care Med*. 2001 Nov 15;164(10 Pt 1):1885-1889.
2. Prasse A. The diagnosis, differential diagnosis, and treatment of sarcoidosis. *Dtsch Arztebl Int*. 2016 Aug 22;113(33-34):565-574. doi: 10.3238/arztebl.2016.0565.
3. Iannuzzi MC, Rybicki BA, Teirstein AS. Sarcoidosis. *N Engl J Med*. 2007 Nov 22;357(21):2153-2165.
4. Judson MA, Thompson BW, Rabin DL, et al; ACCESS Research Group. The diagnostic pathway to sarcoidosis. *Chest*. 2003 Feb;123(2):406-412.
5. Judson MA. Hepatic, splenic, and gastrointestinal involvement with sarcoidosis. *Semin Respir Crit Care Med*. 2002 Dec;23(6):529-541.
6. Judson MA, Boan AD, Lackland DT. The clinical course of sarcoidosis: presentation, diagnosis, and treatment in a large white and black cohort in the United States. *Sarcoidosis Vasc Diffuse Lung Dis*. 2012 Oct;29(2):119-127.
7. Warshauer DM. Splenic sarcoidosis. *Semin Ultrasound CT MR*. 2007 Feb;28(1):21-27.
8. Tu C, Lin Q, Zhu J, et al. Isolated sarcoidosis of accessory spleen in the greater omentum: a case report. *Exp Ther Med*. 2016 Jun;11(6):2379-2384.
9. Kataoka M, Nakata Y, Hiramatsu J, et al. Hepatic and splenic sarcoidosis evaluated by multiple imaging modalities. *Intern Med*. 1998 May;37(5):449-453.
10. Tana C, Tchernev G, Chokoeva AA, et al. Pulmonary and abdominal sarcoidosis, the great imitators on imaging? *J Biol Regul Homeost Agents*. 2016 Apr-Jun;30(2 Suppl 2):45-48.
11. Fetzter DT, Rees MA, Dasyam AK, Tublin ME. Hepatic sarcoidosis in patients presenting with liver dysfunction: imaging appearance, pathological correlation and disease evolution. *Eur Radiol*. 2016 Sep;26(9):3129-3137. doi: 10.1007/s00330-015-4169-2.
12. Brito-Zerón P, Sellarés J, Bosch X, et al. Epidemiologic patterns of disease expression in sarcoidosis: age, gender and ethnicity-related differences. *Clin Exp Rheumatol*. 2016 May-Jun;34(3):380-388.
13. Erra P, Crusco S, Nugnes L, et al. Colonic sarcoidosis: unusual onset of a systemic disease. *World J Gastroenterol*. 2015 Mar 21;21(11):3380-3387. doi: 10.3748/wjg.v21.i11.3380.

This article meets the Accreditation Council for Graduate Medical Education and the American Board of Medical Specialties Maintenance of Certification competencies for Patient Care and Medical Knowledge.