

Use of Sodium Hyaluronate/Carboxymethylcellulose Bioresorbable Membrane in Loop Ileostomy Construction Facilitates Stoma Closure

Danielle M. Bertoni, MD,¹ Kerry L. Hammond, MD,² David E. Beck, MD,^{1,3} Terry C. Hicks, MD,^{1,3} Charles B. Whitlow, MD,^{1,3} H. David Vargas, MD,¹ David A. Margolin, MD^{1,3}

¹Department of Colon and Rectal Surgery, Ochsner Clinic Foundation, New Orleans, LA ²Section of Gastrointestinal and Laparoscopic Surgery, Medical University of South Carolina, Charleston, SC ³The University of Queensland School of Medicine, Ochsner Clinical School, New Orleans, LA

Background: Loop ileostomy is a common adjunct to surgical procedures for low rectal cancers and inflammatory bowel disease. Ileostomy closure through a limited incision can be technically challenging. We hypothesized that placing a sodium hyaluronate/carboxymethylcellulose (SH/CMC) bioresorbable membrane at loop ileostomy creation would decrease stoma closure time without increasing morbidity.

Methods: In a retrospective review at a single institution with 6 board-certified colorectal surgeons, patients with loop ileostomy creation and closure between September 1999 and December 2011 were grouped based on SH/CMC placement at ileostomy creation. Data were abstracted for age, sex, body mass index (BMI), primary diagnosis, length of surgery, staff surgeon, interval between surgeries, and postoperative morbidity. The primary endpoint was the length of the surgery for ileostomy closure. Secondary outcome measures were length of stay, wound infection rate, and other complications.

Results: A total of 293 patients were identified. Group 1 (with SH/CMC) included 146 patients, and Group 2 (without SH/CMC) included 147 patients. The groups were matched according to age, sex, BMI, interval between creation and closure, and indication for surgery. The average surgical time for closure was significantly shorter in Group 1 (46.4 minutes \pm 2.7) compared to Group 2 (60 minutes \pm 2.3) ($P=0.0001$). We found no difference between the groups in length of stay, wound infection rate, or complication rate.

Conclusion: The use of SH/CMC in loop ileostomy creation significantly decreases the operative time required for stoma closure with no increase in the complication rate.

Keywords: Ileostomy, postoperative complications, surgical stomas, tissue adhesions

Address correspondence to David E. Beck, MD, Department of Colon and Rectal Surgery, Ochsner Clinic Foundation, 1514 Jefferson Hwy., New Orleans, LA 70121. Tel: (504) 842-4060. Email: dbeck@ochsner.org

INTRODUCTION

The creation of a loop ileostomy is often a necessary adjunct to surgical procedures for low rectal cancers and inflammatory bowel disease. Several authors have advocated temporary fecal diversion to reduce clinically significant anastomotic dehiscence and to ameliorate the septic consequences of leakage from low pelvic bowel anastomosis.^{1–6} After a variable time interval and assessment of anastomotic integrity by water-soluble contrast enema, intestinal continuity can typically be restored with mobilization of the ileostomy through a limited peristomal incision. In our practice, closure of loop ileostomies is typically performed 5–8 weeks after the index operation for patients who are not undergoing postoperative chemotherapy. Dissection through a limited incision may be impaired due to adhesion

formation at or below the fascial level, resulting in longer operating times and an increased potential for bowel injury.

We have adopted a technique of wrapping the loop of small intestine with an antiadhesion barrier film—sodium hyaluronate/carboxymethylcellulose (SH/CMC) bioresorbable membrane—before its delivery through the abdominal wall for stoma maturation. As SH/CMC has been demonstrated in previous studies to reduce postoperative adhesion development, we hypothesized that the use of SH/CMC would significantly decrease the operating time necessary for ileostomy closure with no effect on infectious complications or other patient morbidities.^{7–9}

METHODS

Following Ochsner Clinic Foundation Institutional Review Board approval, all patients who underwent loop ileostomy

creation and closure at a single tertiary care institution (Ochsner Clinic Foundation, New Orleans, LA) between September 1999 and December 2011 were identified by Current Procedural Terminology (CPT) coding data. A retrospective analysis was performed, with abstraction of data pertaining to patient age, sex, primary diagnosis, operative times, staff surgeon, time interval between surgeries, postoperative morbidity, and whether an SH/CMC wrap was utilized in ileostomy formation.

All surgeries were performed by 6 board-certified colon and rectal surgeons and either colon and rectal surgery residents or general surgery chief residents. Loop ileostomy creation with SH/CMC wrap was performed using a standard 5 × 6-inch sheet of SH/CMC bioresorbable membrane (Seprafilm, Genzyme Corporation). After creation of the stoma opening and prior to delivery of the small intestine through the abdominal wall, SH/CMC was placed on the serosal surface of the chosen portion of bowel, and gentle pressure was applied using a dry laparotomy pad to mold the film to the intestine (Figures 1-3). The bowel was then either grasped with a Babcock clamp or umbilical tape and delivered through the abdominal wall (Figure 4) and matured in customary Brooke fashion. Ileostomy closures were performed by incising the mucocutaneous junction and completely mobilizing both ends of the bowel. After circumferential dissection, a side-to-side 75-mm stapled anastomosis with a stapled or hand-sewn closure of the common enterotomy on the antimesenteric aspect of the small bowel was done.

Study patients were stratified according to SH/CMC placement around the ileostomy at the time of ostomy creation: Group 1 received the SH/CMC wrap; Group 2 did not. Operating time necessary for ileostomy closure through a peristomal incision was considered the primary endpoint for this study. Operating time was defined as the time between skin incision and closure as documented in the operating room records.

Statistical analysis utilizing Fisher exact test (two-tailed), chi-square test, and unpaired *t* test was performed using the Statview software package (SAS Institute). Probability (*P*) values ≤ 0.05 were considered to be statistically significant.

RESULTS

During the 12-year observation period, 293 patients underwent creation and closure of a loop ileostomy: 146 had an SH/CMC wrap placed at the time of ileostomy creation (Group 1), and 147 ileostomies were created without SH/CMC placement (Group 2). No significant differences were found between the 2 groups in age, sex, the time interval between creation and closure of ileostomy, or primary diagnosis (Table 1).

The average operating time for ileostomy closure was significantly shorter for patients in Group 1 (46.4 ± 2.7 minutes) compared to Group 2 (60.0 ± 2.3 minutes) ($P=0.0001$). Our data showed no statistical difference in mean length of stay after stoma closure for either group: 4.6 ± 0.2 days in Group 1 vs 4.9 ± 0.2 days in Group 2 ($P=0.38$).

We found no difference in wound infection at the stoma site adjusted for BMI with or without the use of SH/CMC (Table 2). Group 1 had 8 infections (5.5%) vs 10 infections in Group 2 (6.8%) ($P=0.62$). No increase in other complications including ileus, bleeding, anastomotic leak, or stoma site hernia occurred with the use of SH/CMC ($P=0.3$).

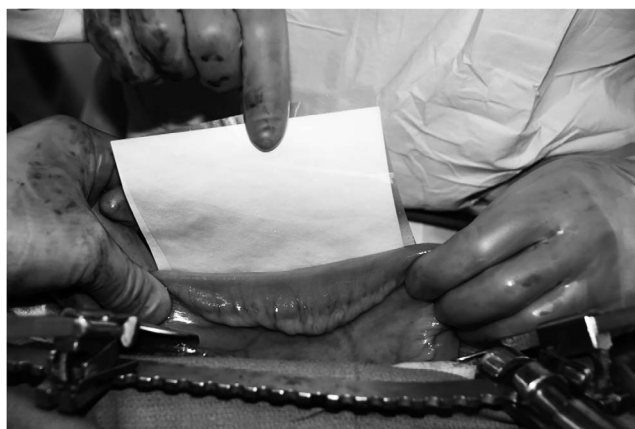

Figure 1. A sheet of sodium hyaluronate/carboxymethylcellulose bioresorbable membrane (Seprafilm) is applied to a section of ileum selected for ileostomy creation. (To see this image in color, click to <https://education.ochsner.org/publishing-services/toc/bertoni-16-0076-fig1>.)

DISCUSSION

The results of our analysis prove our hypothesis that the use of the SH/CMC wrapping technique results in significantly shorter operative times for closure of loop ileostomies with no increase in perioperative complications. Shorter operative times are an objective outcome that may serve as a surrogate marker of adhesion formation and operative difficulty. An easier operation is especially important when working with small peristomal incisions and surgical trainees.

In contrast to previous studies, our study is based on results from a single group of board-certified colon and rectal surgeons who use relatively uniform techniques for ileostomy creation, SH/CMC placement, and ileostomy closure.

In a 2003 study, Tang et al randomized patients into 2 treatment groups (ileostomy creation with and without placement of SH/CMC at the ileostomy site).¹⁰ In phase I of the trial, patients with SH/CMC-wrapped ileostomies ($n=51$) were assessed by water-soluble enema for ileostomy

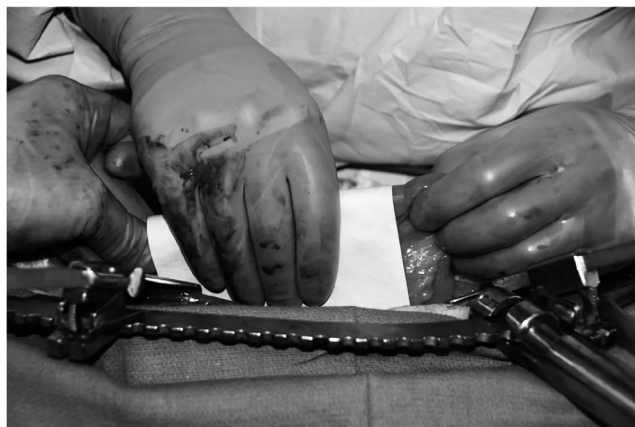

Figure 2. A sheet of sodium hyaluronate/carboxymethylcellulose bioresorbable membrane (Seprafilm) with Tevdek backing is wrapped around the piece of ileum. (To see this image in color, click to <https://education.ochsner.org/publishing-services/toc/bertoni-16-0076-fig2>.)

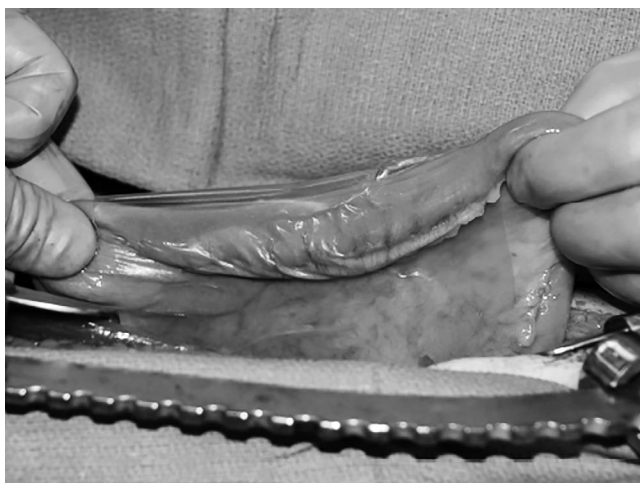

Figure 3. The ileum is wrapped in a sodium hyaluronate/carboxymethylcellulose bioresorbable membrane (Seprafil). (To see this image in color, click to <https://education.ochsner.org/publishing-services/toc/bertoni-16-0076-fig3>.)

reversal 3 weeks after the index operation, while ostomies created without SH/CMC wraps ($n=54$) were assessed after 6-12 weeks. Phase II of the trial was designed with assessment of both treatment groups for ileostomy closure 3 weeks postoperatively. The mean 4-quadrant adhesion scores, as assessed by the surgeon at the time of ileostomy closure, were significantly lower for ileostomies created with an adhesion barrier (SH/CMC). The adhesion barrier patient group also had significantly lower perioperative complications. However, Tang et al found no difference in operative time with the use of SH/CMC.

In a 2006 multicenter, randomized trial, Salum et al evaluated adhesion grade, operative time, and postoperative complications.¹¹ Patients from 15 institutions were prospectively randomized into 3 groups: Group 1 had placement of SH/CMC around the ostomy and midline, Group 2 had SH/CMC placed under the midline only, and Group 3 had no SH/CMC placement. The adhesion grade at the time of ileostomy closure was significantly lower for patients in Group 1 compared to Group 3; however, lower adhesion grade did not translate into a significant difference in operative time.

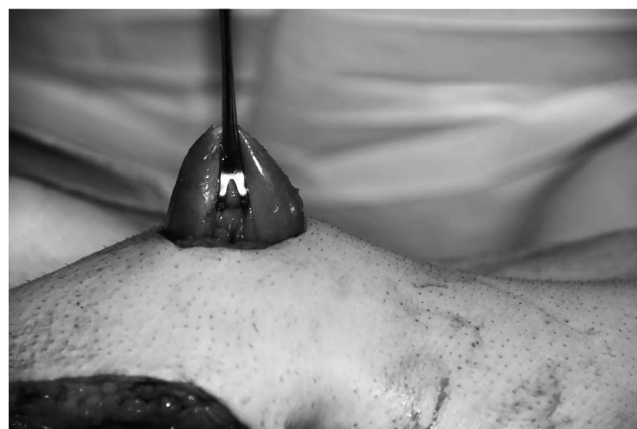


Figure 4. A loop of ileum covered with sodium hyaluronate/carboxymethylcellulose bioresorbable membrane (Seprafil) is brought through the abdominal wall opening prior to maturation. (To see this image in color, click to <https://education.ochsner.org/publishing-services/toc/bertoni-16-0076-fig4>.)

In a 2012 publication, Memon et al in Australia performed a case-matched study that showed SH/CMC wrapping of ileostomies could facilitate early stoma closure.¹² Thirty-two patients selected for early closure protocol were retrospectively matched with patients who had conventional closure. The early closure protocol included wrapping the ileostomy in SH/CMC and a planned closure at 4-6 weeks if contrast enema showed no evidence of leak. Ultimately, 22 patients had early closure with a median closure at 55 days compared to 213 days in the conventional group ($P<0.001$). No differences in complications or length of stay were seen between the 2 groups.

Our study has several limitations. Because of the retrospective design, we could not evaluate the effect of SH/CMC placement on adhesion grade, which is a subjective assessment made by the operating surgeon at the time of ileostomy closure. Our surgeons all felt the operation was easier with SH/CMC; however, this subjective statement is not supported by any method of objective measurement. Also, our groups were not randomized, so some bias in terms of which surgeons used the SH/CMC

Table 1. Patient Characteristics by Treatment Group

	Group 1 with SH/CMC n=146	Group 2 without SH/CMC n=147	P Value
Mean age, years \pm SD	46.4 \pm 16.9	44.8 \pm 15.6	0.52
Male, n (%)	77 (52.7)	79 (53.7)	1.00
Mean interval between surgeries, days \pm SD	92.7 \pm 92.8	109.6 \pm 115.2	0.30
Primary diagnosis, n (%)			
Inflammatory bowel disease	77 (52.7)	86 (58.5)	0.54
Neoplasm	54 (37.0)	35 (23.8)	0.06
Prolapse, benign fistula, ischemia, Hirschsprung disease, and diverticulitis	13 (8.9)	17 (11.6)	0.62
Familial adenomatous polyposis	2 (1.4)	9 (6.1)	0.15

SH/CMC, sodium hyaluronate/carboxymethylcellulose bioresorbable membrane (Seprafil).

Table 2. Postoperative Complications by Treatment Group

	Group 1 with SH/CMC n=146	Group 2 without SH/CMC n=147	P Value
Infections	8 (5.5)	10 (6.8)	0.62
Ileus	12 (8.2)	14 (9.5)	0.73
Bleeding	0 (0)	0 (0)	0.97
Anastomotic leak	1 (0.7)	2 (1.4)	0.89
Stoma site hernia	4 (2.7)	4 (2.7)	0.96

Note: Data are reported as n (%).

SH/CMC, sodium hyaluronate/carboxymethylcellulose bioresorbable membrane (Seprafilm).

wrapping technique could be present. The lack of statistical difference when each individual surgeon's experience was analyzed most likely reflects the small sample size for each surgeon and is a type II error. The lack of statistical significance in a subset analysis of the neoplasm group was also a type II error.

The mean interval between creation and closure of 92.7 days for Group 1 and 109.6 days for Group 2 is typical of our practice. The majority of the surgeons in this practice close the ileostomy in patients with cancer after completion of postoperative chemotherapy (usually approximately 6 months). When looking at the model, we found that the mean interval between surgeries was 58 days for Group 1 and 63 days for Group 2, reflecting the practice of closing the ileostomy in patients not receiving postoperative chemotherapy at 5-8 weeks.

While a formal cost analysis was not performed, the cost of one sheet of SH/CMC is approximately \$150, and the cost of operating room time at our institution is approximately \$80-\$100 per minute. Thus, the use of SH/CMC potentially saves \$1,088 to \$1,360 per case.

CONCLUSION

Based on our experience, the use of an antiadhesion product has become standard practice when creating our diverting ileostomies. Not only did we find a significant difference in operating time with the use of SH/CMC (14 minutes faster overall), but our surgeons all felt that the ileostomy closure was easier when they used SH/CMC. Since the completion of this study, the use of SH/CMC has become standard practice at our institution. While a randomized controlled trial that includes evaluation of adhesion grades would be ideal and give further credence to our hypothesis, given the significant difference in operating times with the use of SH/CMC without increased morbidity, we feel that such a study would add very little. However, questions remain as to the cost effectiveness of SH/CMC in other surgical procedures, and further studies are indicated.

ACKNOWLEDGMENTS

The authors thank Elizabeth C. Margolin and Heather Greene Matrana for their assistance in data collection. The authors have no financial or proprietary interest in the subject matter of this article.

REFERENCES

- Matthiessen P, Hallböök O, Rutegård J, Simert G, Sjødahl R. Defunctioning stoma reduces symptomatic anastomotic leakage after low anterior resection of the rectum for cancer: a randomized multicenter trial. *Ann Surg* 2007 Aug;246(2):207-214.
- Graffner H, Fredlund P, Olsson SA, Oscarson J, Petersson BG. Protective colostomy in low anterior resection of the rectum using the EEA stapling instrument. A randomized study. *Dis Colon Rectum*. 1983 Feb;26(2):87-90.
- Pakkastie TE, Ovaska JT, Pekkala ES, Luukkonen PE, Järvinen HJ. A randomised study of colostomies in low colorectal anastomoses. *Eur J Surg*. 1997 Dec;163(12):929-933.
- Pimentel JM, Duarte A, Patricio J. The role of a protecting stoma in low anterior resection with TME and colonic J-pouch for rectal cancer: Results of a prospective randomized trial. *Colorectal Dis*. 2003;5(suppl. 2):83.
- Hüser N, Michalski CW, Erkan M, et al. Systematic review and meta-analysis of the role of defunctioning stoma in low rectal cancer surgery. *Ann Surg*. 2008 Jul;248(1):52-60. doi: 10.1097/SLA.0b013e318176bf65.
- Weston-Petrides GK, Lovegrove RE, Tilney HS, et al. Comparison of outcomes after restorative proctocolectomy with or without defunctioning ileostomy. *Arch Surg*. 2008 Apr;143(4):406-412. doi: 10.1001/archsurg.143.4.406.
- Cohen Z, Senagore AJ, Dayton MT, et al. Prevention of postoperative abdominal adhesions by a novel, glycerol/sodium hyaluronate/carboxymethylcellulose-based bioresorbable membrane: a prospective, randomized, evaluator-blinded multicenter study. *Dis Colon Rectum*. 2005 Jun;48(6):1130-1139.
- Becker JM, Dayton MT, Fazio VW, et al. Prevention of postoperative abdominal adhesions by a sodium hyaluronate-based bioresorbable membrane: a prospective, randomized, double-blind multicenter study. *J Am Coll Surg*. 1996 Oct;183(4):297-306.
- Vrijland WW, Tseng LN, Eijkman HJ, et al. Fewer intraperitoneal adhesions with use of hyaluronic acid-carboxymethylcellulose membrane: a randomized clinical trial. *Ann Surg*. 2002 Feb;235(2):193-199.
- Tang CL, Seow-Choen F, Fook-Chong S, Eu KW. Bioresorbable adhesion barrier facilitates early closure of the defunctioning ileostomy after rectal excision: a prospective, randomized trial. *Dis Colon Rectum*. 2003 Sep;46(9):1200-1207.
- Salum M, Wexner SD, Nogueras JJ, et al; Program Directors Association in Colon and Rectal Surgery. Does sodium hyaluronate- and carboxymethylcellulose-based bioresorbable membrane (Seprafilm) decrease operative time for loop ileostomy closure? *Tech Coloproctol*. 2006 Oct;10(3):187-190; discussion 190-191.
- Memon S, Heriot AG, Atkin CE, Lynch AC. Facilitated early ileostomy closure after rectal cancer surgery: a case-matched study. *Tech Coloproctol*. 2012 Aug;16(4):285-290. doi: 10.1007/s10151-012-0843-4.

This article meets the Accreditation Council for Graduate Medical Education and the American Board of Medical Specialties Maintenance of Certification competencies for Patient Care, Medical Knowledge, and Practice-Based Learning and Improvement.