The Ochsner Journal 13:389–393, 2013
© Academic Division of Ochsner Clinic Foundation

Effective Use of Bronchial Blockers in Lung Isolation Surgery: An Analysis of 130 Cases

Logan Kosarek, MD,* Eric Busch, MD,*‡ Abbas Abbas, MD,†‡,1 Jason Falterman, MD,* Bobby D. Nossaman, MD*

**Department of Anesthesiology and*
†Department of Surgery, Ochsner Clinic Foundation, and
‡The University of Queensland School of Medicine, Ochsner Clinical School, New Orleans, LA

ABSTRACT

Background: One-lung ventilation (OLV) is necessary for selected surgical settings and medical conditions. Different methods have been described and used to isolate 1 lung, including the double-lumen endotracheal tube (DLT) and a variety of bronchial blockers (BBs). This selection is often based on the preferences and experiences of the anesthesiologist and surgeon. Complications associated with OLV isolation tubes have been previously described, but complications specifically associated with the Cohen BB (CBB) (Cook Medical, Bloomington, IN) have not been investigated. The purpose of this retrospective review was to determine the incidence of vocal cord injury, tracheobronchial injury, and hoarseness in adult patients who underwent OLV with the CBB.

Methods: We reviewed electronic anesthesia records, operative dictation, and inpatient progress notes to collect information about vocal cord injury, bronchial injury, hoarseness, and sore throat for adults who underwent surgical and diagnostic procedures requiring OLV. Secondary endpoints were types of surgical procedures, degree of difficulty with orotracheal intubation, ability of the patient to tolerate extubation in the operating room, and whether the thoracic surgeon deemed the lung separation adequate. $P<0.05$ was considered significant.

Results: Of 130 patients, 113 underwent OLV with a CBB, and 17 patients underwent OLV with a DLT. The thoracic surgeon deemed the lung isolation adequate in all cases. Airway injury occurred in 2 patients with a CBB and none with a DLT ($P=0.86$). Both airway injuries were attributed to surgical technique. Two cases of postoperative hoarseness occurred in the CBB group ($P=0.86$). One injury was attributed to vagus nerve transection, and the other injury was diagnosed as vocal cord paralysis of unknown etiology. In 1 case, orotracheal intubation with a DLT was unsuccessful because of intubation difficulty and required conversion to a regular endotracheal tube and CBB for successful lung isolation.

Conclusion: This study demonstrates that the use of CBB can be successful in a wide variety of thoracic operations, has minimal complications, eliminates the need for tracheal tube exchange when postoperative mechanical ventilation is required, and effectively isolates the lungs of critically ill patients.

Address correspondence to
Eric Busch, MD
Department of Anesthesiology
Ochsner Clinic Foundation
1514 Jefferson Hwy.
New Orleans, LA 70121
Tel: (504) 842-3011
Fax: (504) 842-2036
Email: ebusch@ochsner.org

Keywords: Bronchi, intubation–intratracheal, one-lung ventilation, thoracic surgical procedures

The authors have no financial or proprietary interest in the subject matter of this article.

[1]Dr Abbas is now with the Department of Thoracic Surgery at Temple University Hospital and the Department of Surgery at Temple University School of Medicine, Philadelphia, PA.

INTRODUCTION

Numerous clinical indications for one-lung ventilation (OLV) exist.[1-5] Satisfactory OLV can be achieved via a double-lumen tube (DLT) or a bronchial blocker (BB). Certain clinical situations, such as lung lavage for severe pulmonary alveolar proteinosis, require the use of a DLT,[1] but often the method of OLV is left to the preference and experience of the anesthesiologist in consultation with the surgeon. Although DLTs are more popular, the use of BBs is increasing.[6,7]

BBs offer benefits over DLTs. For example, a BB can be quickly inserted through an established single-lumen tube (SLT) during surgery,[6] avoiding the technical challenges associated with insertion of the large and, at times, awkward DLT.[8,9] Most thoracic

procedures require preoperative bronchoscopy that cannot be performed through a DLT and would otherwise require a second reintubation of the trachea. During esophagectomy, the blocker is employed during the thoracic portion of the surgical procedure and is then removed for the abdominal component. The smaller profile of the SLT makes surgical dissection of the airway and esophagus easier and safer.[10] Moreover, in difficult airways, the BB allows SLT placement using a variety of techniques not compatible with the DLT.[7,11-13] The use of the BB also avoids postoperative orotracheal tube exchange if postoperative ventilation is required. Furthermore, continuous intraoperative observation of the blocker position in relationship to the airway anatomy is possible with a fiberscope placed above the carina, which is not possible with the DLT.

Once the anesthesiologist has decided to use a BB, many different models are available. The first tool specifically designed for bronchial blockade was the Univent torque control blocker (LMA Vitaid, Lewiston, NY) introduced in 1982.[14] Over the past 20 years, several new, specialized orotracheal tubes have been introduced. The Cohen BB (CBB; Cook Medical, Bloomington, IN) facilitates placement into either the left or right mainstem bronchus by way of a steerable tip that can be easily maneuvered into place with a control wheel (Figure).[15] This technique is novel and less cumbersome compared to other methods used to facilitate BB placement.[16-18]

Previous studies comparing the BB and the DLT have focused on the quality of lung isolation, time to lung collapse, malpositioning, and airway injury; the results of those studies have varied.[17,19-24] One prospective study observed a reduced incidence of hoarseness, sore throat, and vocal cord injuries with the Arndt BB (Cook Medical) compared to the DLT.[20]

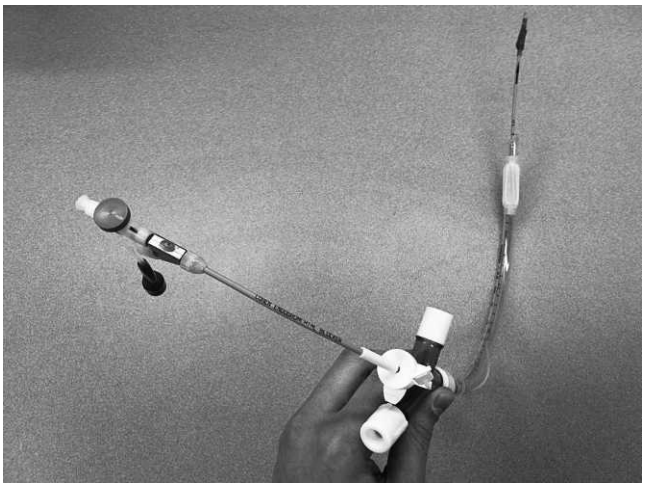

Figure. Cohen bronchial blocker with adaptor.

However, airway complications associated with the CBB have not been investigated. The purpose of this retrospective review was to determine the incidence of vocal cord injury, bronchial injury, hoarseness, and sore throat in adult patients who underwent general anesthesia via the CBB.

METHODS

After receiving institutional review board approval, we performed a retrospective review of charts from January through December 2009. All cases were performed by the same thoracic surgeon. Records were screened to include adults (age >17 years) undergoing surgical and diagnostic procedures that required OLV. We excluded patients if they had a history of previous airway injury or if the trachea was intubated with an orotracheal or tracheostomy tube at the time of surgery. Airway management and placement of either the DLT or BB were performed by either an attending anesthesiologist or an anesthesia resident. Residents performing the procedure were closely supervised by the attending anesthesiologist.

Data were collected from the electronic anesthesia record (DocuSys Anesthesia, Merge Healthcare, Chicago, IL), operative dictation, and inpatient progress notes (Horizon Patient Folder, Merge Healthcare). The primary endpoints of the study were the incidence of vocal cord injury, bronchial injury, hoarseness, and sore throat. Secondary endpoints were the types of surgical procedures, degree of difficulty with orotracheal intubation, ability of the patient to tolerate extubation in the operating room, and whether the thoracic surgeon involved in all the cases deemed the lung isolation adequate. Categorical variables were expressed as percentages, and differences between the groups were assessed using chi-square or Fisher exact tests. Continuous variables with nonskewed distributions were expressed as mean and standard deviation, and differences between groups were assessed using the Student *t* test. Continuous variables with skewed distributions were expressed as median and interquartile range, and differences between groups were assessed by the Wilcoxon rank sum test. P values <0.05 were defined as statistically significant.

RESULTS

We included 130 patients in the study, dividing them into 2 groups. The CBB group had 113 patients (64 had right-sided isolation; 49 had left-sided isolation), and the DLT group had 17 patients (all left-sided DLTs). Demographics and findings are presented in the Table. The difference in the ratio of women to men in the CBB group as opposed to the DLT group was statistically significant. Airway injury

Table. Demographics and Treatment Details for Patients Undergoing One-Lung Ventilation

	Cohen Bronchial Blocker Group	Double-Lumen Tube Group	P Value
Patients	113	17	
Age (yrs)	65.7 ± 14.3	57.4 ± 19.5	0.11
Weight (kg)	77.6 ± 14.5	84.6 ± 21.6	0.21
Height (in)	64.5 ± 4.3	67.2 ± 7.7	0.18
Gender: male/female	49/64	12/5	0.04[a]
Modified Mallampati score	2 (1-4)	2 (1-3)	0.42
ASA PS score	III (I-IV)	III (I-III)	0.22
Difficult intubation	7 (6%)[b]	0[b]	0.57
Side: left/right/bilateral	60/53/0	5/9/3	0.0001[a]
Airway injury	2[c]	0	0.86
Postoperative hoarseness	2[d]	0	0.86
Tube exchanged	0	15 (88%)	0.0001[a]
Extubated in operating room	96 (85%)	17 (100%)	0.23
One-lung ventilation adequate	113 (100%)	17 (100%)	1
Duration of surgery (min)	215.4 ± 104.4	192.9 ± 66.2	0.24
Surgical procedures performed	Wedge resection (38), lobectomy (17), esophagectomy (13), segmentectomy (11), decortication (7), blebectomy (6), pleurodesis (4), lysis of adhesions (3), pneumonectomy (3), chest wall mass excision (3), lymph node dissection (2), bilobectomy (2), esophageal fistula repair (1), hematoma evacuation (1), esophageal myotomy (1), diaphragmatic hernia repair (1)	Lobectomy (7), wedge resection (4), segmentectomy (2), sympathectomy (2), pleurodesis (1), lung reduction (1)	

Values are mean ± standard deviation (age, weight, height, duration of surgery) or median and range (modified Mallampati score, ASA PS [American Society of Anesthesiologists Physical Status Score]). All other values are numbers.

[a]*P* value is statistically significant.

[b]In one case, orotracheal intubation with a double-lumen tube was unsuccessful because of airway difficulty. A single-lumen tube was substituted for orotracheal intubation and a bronchial blocker utilized for successful lung isolation.

[c]The operative report attributed both airway injuries to surgical technique.

[d]Two cases of postoperative hoarseness occurred, both in the bronchial blocker group. One injury was attributed to vagus nerve transection, and the other injury was diagnosed as vocal cord paralysis with an unknown etiology.

occurred in 2 patients with a CBB but none of the patients with a DLT (P=0.86). The operative reports attributed both airway injuries to surgical technique. Two cases of postoperative hoarseness occurred in the BB group (P=0.86): One injury was attributed to vagus nerve transection, and the other injury was diagnosed as vocal cord paralysis of unknown etiology. The thoracic surgeon deemed the lung isolation adequate in all cases regardless of the method used to achieve OLV. However, we found a highly significant incidence of the DLT being exchanged for a conventional SLT for postoperative mechanical ventilation in cases when a DLT was initially used for lung isolation ($P<0.0001$). In 1 case, orotracheal intubation with a DLT was unsuccessful because of airway difficulty; an SLT was substituted for orotracheal intubation, and a BB was used for successful lung isolation. With regard to the other secondary endpoints of this study, we found no significant differences.

DISCUSSION

In this retrospective review, we compared several aspects of BB and DLT use, focusing on the incidence of airway complications. We found no significant difference between the 2 devices with regard to airway complications, a distinction Knoll et al[22] observed in a previous study. Although Knoll et al[22] reported few airway complications, significantly more tube exchanges were made when the DLT was used. We did not observe difficulty with exchanging a DLT with an SLT for postoperative mechanical ventilation, but others have reported that such exchanges involve suboptimal reintubation conditions and constitute a risk factor for postoperative airway complications.[18]

For all of our patients, the thoracic surgeon deemed the lung isolation adequate. External tracheal manipulation by the thoracic surgeon facilitated the success of lung isolation during CBB placement but may have played a role in postoperative hoarseness rates. Familiarity with BBs and facility with their placement are essential skills for anesthesiologists, especially in cases requiring OLV, in which BBs have been shown to have an advantage over DLTs. These cases include patients who are critically ill and intubated, who have an established tracheostomy, who are known to have difficult airways, or who may require nasotracheal intubation.[7,8,11,25-29]

One obvious limitation of this study is the retrospective design. Although detailed perioperative notes in the electronic records by the thoracic surgeon and the anesthesiologists lessen the limitations of retrospective chart reviews, this type of review may miss complications. Another possible limitation is the development of acute, transient, postoperative hoarseness that may not have been fully documented, suggesting that these complaints are minor. Additionally, technical problems related to BB and DLT insertion may have been omitted from the electronic anesthesia record, introducing clinical bias. We consider this possibility unlikely because the clinical team involved was facile with both techniques. Following completion of the procedure, the surgeon qualitatively described the adequacy of OLV. Moreover, no intraoperative failure of either technique was noted in the surgical or anesthesia records.

CONCLUSIONS

This study clearly demonstrates that CBB can be successfully used in a wide variety of thoracic operations, has minimal complications, eliminates the need for tracheal tube exchange, and provides the ability to effectively isolate lungs in critically ill patients, patients with difficult airways, or patients with tracheostomies, which are all known limitations of DLTs.

REFERENCES

1. Webb ST, Evans AJ, Varley AJ, Klein AA. Anaesthesia for serial whole-lung lavage in a patient with severe pulmonary alveolar proteinosis: a case report. *J Med Case Rep*. 2008 Nov 27;2:360.
2. Ng JM. Update on anesthetic management for esophagectomy. *Curr Opin Anaesthesiol*. 2011 Feb;24(1):37-43.
3. Lohser J. Evidence-based management of one-lung ventilation. *Anesthesiol Clin*. 2008 Jun;26(2):241-272.
4. Mirzabeigi E, Johnson C, Ternian A. One-lung anesthesia update. *Semin Cardiothorac Vasc Anesth*. 2005 Sep;9(3):213-226.
5. Anantham D, Jagadesan R, Tiew PE. Clinical review: independent lung ventilation in critical care. *Crit Care*. 2005;9(6):594-600. Epub 2005 Oct 10.
6. Ho AM, Ng SK, Tsang KH, et al. A technique that may improve the reliability of endobronchial blocker positioning during adult one-lung anaesthesia. *Anaesth Intensive Care*. 2009 Nov;37(6):1012-1016.
7. Campos JH. Lung isolation techniques for patients with difficult airway. *Curr Opin Anaesthesiol*. 2010 Feb;23(1):12-17.
8. DeGregoris G, Hill SS, Slepian RL. Airtraq laryngoscope for bronchial blocker placement in a difficult airway. *Anaesthesia*. 2009 Jun;64(6):691-692.
9. Satya-Krishna R, Popat M. Insertion of the double lumen tube in the difficult airway. *Anaesthesia*. 2006 Sep;61(9):896-898.
10. Yamase H, Okuda I, Udagawa H, Kohno T, Sumida T. Which tube is better for esophagectomy? [in Japanese]. *Kyobu Geka*. 2009 May;62(5):347-351; discussion 351-353.
11. Brodsky JB. Lung separation and the difficult airway. *Br J Anaesth*. 2009 Dec;103(Suppl 1):i66-i75.
12. Cohen E, Benumof JL. Lung separation in the patient with a difficult airway. *Curr Opin Anaesthesiol*. 1999 Feb;12(1):29-35.
13. Harvey SC, Alpert CC, Fishman RL. Independent placement of a bronchial blocker for single-lung ventilation: an alternative method for the difficult airway. *Anesth Analg*. 1996 Dec;83(6):1330-1331.
14. Inoue H, Shohtsu A, Ogawa J, Kawada S, Koide S. New device for one-lung anesthesia: endotracheal tube with movable blocker. *J Thorac Cardiovasc Surg*. 1982 Jun;83(6):940-941.
15. Cohen E. The Cohen Flexi-Tip endobronchial blocker: an alternative to a double lumen tube. *Anesth Analg*. 2005 Dec; 101(6):1877-1879.
16. Arndt GA, Kranner PW, Lorenz D. Co-axial placement of endobronchial blocker. *Can J Anaesth*. 1994 Nov;41(11):1126-1127.
17. Narayanaswamy M, McRae K, Slinger P, et al. Choosing a lung isolation device for thoracic surgery: a randomized trial of three bronchial blockers versus double-lumen tubes. *Anesth Analg*. 2009 Apr;108(4):1097-1101.
18. Gayes JM. Pro: one-lung ventilation is best accomplished with the Univent endotracheal tube. *J Cardiothorac Vasc Anesth*. 1993 Feb;7(1):103-107.
19. Campos JH, Kernstine KH. A comparison of a left-sided Broncho-Cath with the torque control blocker univent and the wire-guided blocker. *Anesth Analg*. 2003 Jan;96(1):283-289.
20. Bauer C, Winter C, Hentz JG, Ducrocq X, Steib A, Dupeyron JP. Bronchial blocker compared to double-lumen tube for one-lung ventilation during thoracoscopy. *Acta Anaesthesiol Scand*. 2001 Feb;45(2):250-254.
21. Campos JH, Reasoner DK, Moyers JR. Comparison of a modified double-lumen endotracheal tube with a single-lumen tube with enclosed bronchial blocker. *Anesth Analg*. 1996 Dec;83(6):1268-1272.

22. Knoll H, Ziegeler S, Schreiber JU, et al. Airway injuries after one-lung ventilation: a comparison between double-lumen tube and endobronchial blocker: a randomized, prospective, controlled trial. *Anesthesiology*. 2006 Sep;105(3):471-477.
23. Ruetzler K, Grubhofer G, Schmid W, et al. Randomized clinical trial comparing double-lumen tube and EZ-Blocker for single-lung ventilation. *Br J Anaesth*. 2011 Jun;106(6):896-902. Epub 2011 Apr 14.
24. Dumans-Nizard V, Liu N, Laloë PA, Fischler M. A comparison of the deflecting-tip bronchial blocker with a wire-guided blocker or left-sided double-lumen tube. *J Cardiothorac Vasc Anesth*. 2009 Aug;23(4):501-505. Epub 2009 Apr 10.
25. Angie Ho CY, Chen CY, Yang MW, Liu HP. Use of the Arndt wire-guided endobronchial blocker via nasal for one-lung ventilation in patient with anticipated restricted mouth opening for esophagectomy. *Eur J Cardiothorac Surg*. 2005 Jul;28(1):174-175. Epub 2005 Apr 18.
26. Vretzakis G, Theodorou E, Mikroulis D. Endobrochial blockade through a tracheostomy tube for lung isolation. *Anesth Analg*. 2008 Nov;107(5):1644-1645.
27. Dhamee MS. One-lung ventilation in a patient with a fresh tracheostomy using the tracheostomy tube and a Univent endobronchial blocker. *J Cardiothorac Vasc Anesth*. 1997 Feb; 11(1):124-125.
28. Arndt GA, Kranner PW, Rusy DA, Love R. Single-lung ventilation in a critically ill patient using a fiberoptically directed wire-guided endobronchial blocker. *Anesthesiology*. 1999 May;90(5):1484-1486.
29. Klein U, Karzai W, Zimmermann P, et al. Changes in pulmonary mechanics after fiberoptic bronchoalveolar lavage in mechanically ventilated patients. *Intensive Care Med*. 1998 Dec;24(12):1289-1293.

This article meets the Accreditation Council for Graduate Medical Education and the American Board of Medical Specialties Maintenance of Certification competencies for Patient Care and Medical Knowledge.