The Ochsner Journal 15:97–101, 2015
© Academic Division of Ochsner Clinic Foundation

Early Precursor of Mixed Endocrine-Exocrine Tumors of the Gastrointestinal Tract: Histologic and Molecular Correlations

Fateh Bazerbachi, MD,[1]* Taher R. Kermanshahi, MD,[2]* Carmela Monteiro, MD[2]

[1]*Department of Medicine, University of Minnesota, Minneapolis, MN*
[2]*Department of Pathology and Laboratory Medicine, University of Florida, Jacksonville, FL*

ABSTRACT

Background: Mixed endocrine-exocrine tumors display histologic features of endocrine and glandular differentiation. Unlike in collision tumors, the two components are thought to arise from a monoclonal precursor. Evidence from molecular testing supports the monoclonal theory and suggests that the exocrine component may give rise to the endocrine component but not vice versa.

Case Report: We report a case of an adenomatous polyp in the large intestine that had groups of endocrine cells arising from the crypt bases of the adenomatous (exocrine) epithelium. To our knowledge, ours is only the second report of an adenomatous polyp in which groups of microcarcinoid endocrine cells were recognized. The histologic findings in our case correlate with the molecular findings described in mixed endocrine-exocrine tumors.

Conclusion: Our description may represent the primordial stage of a mixed endocrine-exocrine neoplasm.

INTRODUCTION

Mixed endocrine-exocrine neoplasms of the gastrointestinal (GI) tract are rare tumors that demonstrate two heterogeneous histologic components, namely endocrine and glandular (exocrine) components. The endocrine component can be poorly differentiated or well differentiated (ie, carcinoid tumor). Similarly, the exocrine component can be adenomatous or carcinomatous. The endocrine component comprises one-third to one-half of the tumor bulk and can either admix intimately and diffusely with the exocrine component (combined tumor) or exist in a separate area with a transition zone between the two components (composite tumor).[1] Alternatively, endocrine-exocrine collision tumors are composed of two topographically distinct components and as such are not considered mixed.[2] Mixed tumors may demonstrate malignancy that usually involves the exocrine component, whereas simultaneous growth of an adenoma and a carcinoid is rare.[3] Considering the degree of heterogeneity in grade and differentiation, different combinations have been reported (Table). Therefore, it is not surprising that some of these tumors will exhibit a benign behavior, while others may be aggressively invasive and metastatic (with distant metastases being endocrine or exocrine).[4,5-8] One report described distant lymph node metastases containing both components with a transition zone, identical to the original tumor.[9] These tumors can emerge anywhere in the GI tract, including the esophagus (usually in the setting of Barrett esophagus),[10] stomach,[9] small intestine,[8] cecum,[4] colon,[11,12] rectum,[13,14] and anal canal.[15] They can occur with other GI conditions, such as atrophic gastritis[16] or familial adenomatous polyposis syndrome.[17] The origin of these tumors and whether both components share a mutual precursor have been subjects of debate.

In 2006, Pulitzer et al described four cases of adenomatous polyps in the large intestine with concomitant microcarcinoid, an entity that had not been described previously, and discussed its histologic and immunohistochemical attributes.[18] In this article, we report a case that further characterizes this entity and its histogenesis.

Address correspondence to
Carmela Monteiro, MD
Department of Pathology and Laboratory Medicine
University of Florida
655 West 8th St.
Jacksonville, FL 32209
Tel: (904) 244-4699
Email: carmela.monteiro@jax.ufl.edu

Keywords: Adenomatous polyps, carcinoid tumor, gastrointestinal neoplasms

**These authors contributed equally to this work.*

The authors have no financial or proprietary interest in the subject matter of this article.

Table. Examples of Different Combinations of Exocrine and Endocrine Components in Terms of Differentiation and Grade

Reference	Location	Exocrine Component	Endocrine Component
Furlan et al[2]	Colon	Adenocarcinoma	Well-differentiated endocrine tumor (carcinoid)
Doğan et al[4]	Cecum	Adenocarcinoma	Poorly differentiated endocrine carcinoma
Masson[5]	Colon	Adenoma	Well-differentiated endocrine tumor (carcinoid)
Thompson et al[6]	Terminal ileum	Adenoma	Well-differentiated endocrine carcinoma (malignant carcinoid)

Note: The diagnoses given in this table for the endocrine component are not necessarily the ones mentioned in the original reference. Rather, they are the appropriate diagnoses in accordance with World Health Organization classification based on the histologic description of each case in the article where it is reported.[7]

CASE REPORT

A 72-year-old man underwent colonoscopy screening. Two polyps, a 0.3 cm sessile polyp in the ascending colon and a 2.0 cm pedunculated polyp in the descending colon, were discovered.

Histology

Evaluation of the hematoxylin and eosin stained slides of the descending colon polyp revealed tubulovillous adenoma with no high-grade dysplasia (Figure). Careful examination of the base of the crypts

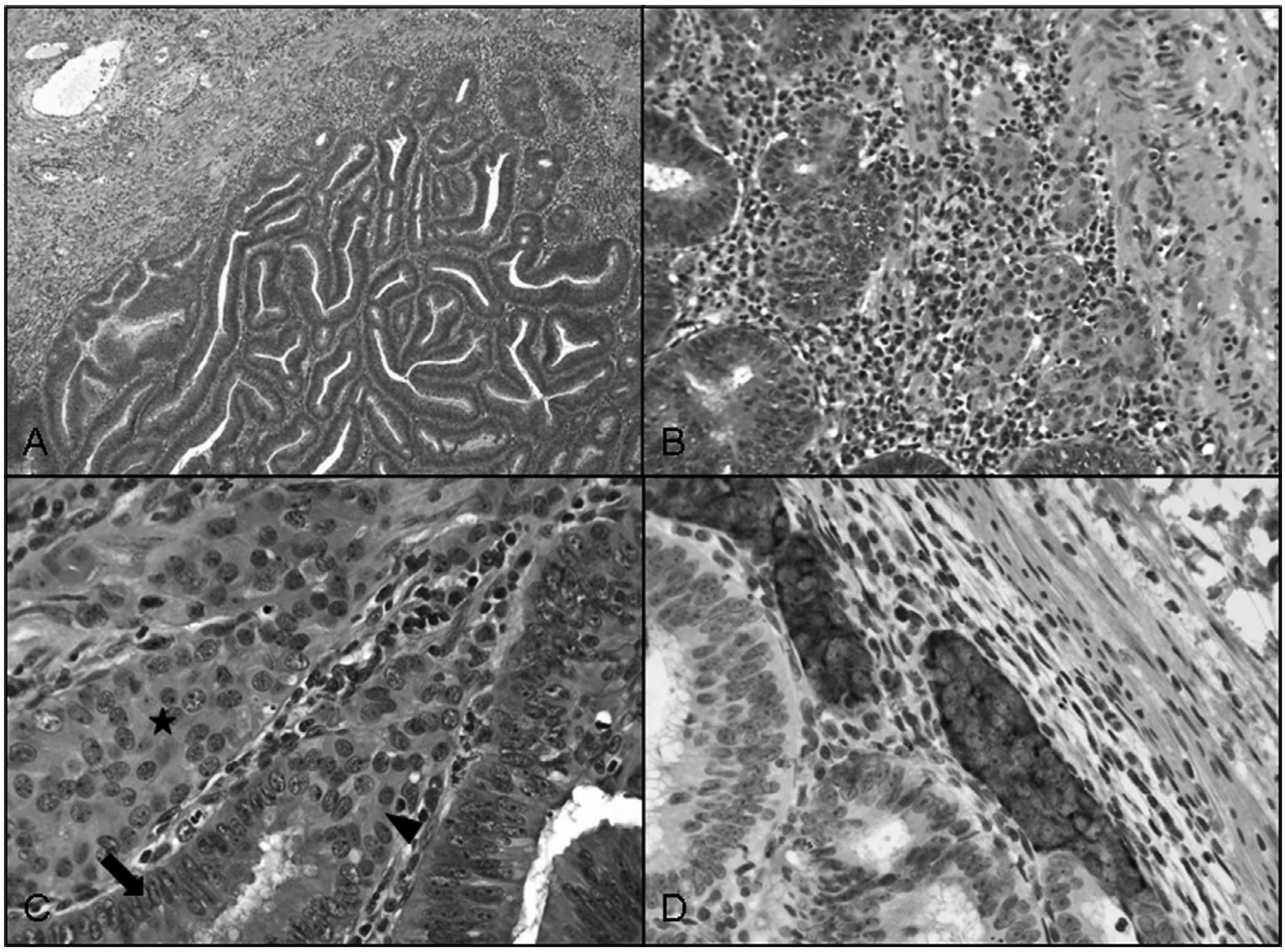

Figure. A: On low magnification, a small endocrine component might be overlooked (hematoxylin and eosin, 4×). B: On medium magnification, groups of cells with endocrine features can be seen (hematoxylin and eosin, 20×). C: An area of transition between usual adenomatous epithelium (arrow) to adenomatous epithelium with more abundant eosinophilic cytoplasm (arrowhead) to nests of endocrine cells (star) (hematoxylin and eosin, 40×). D: Endocrine cells and the adjacent adenomatous epithelium stain positive with synaptophysin, while the usual adenomatous epithelium is negative (hematoxylin and eosin, 40×).

to rule out microscopic invasion revealed multiple minute foci of morphologically distinct groups of cells that had many features of well-differentiated endocrine (carcinoid) tumors. These cells were arranged in nests, cords, irregular clusters, and single cells and appeared to superficially invade the muscularis mucosa. They had relatively abundant eosinophilic, granular cytoplasm and bland, round, central nuclei with finely stippled chromatin. Most of the nuclei had a small central nucleolus. No mitotic figures were identified within these groups of cells. These foci were present in multiple areas throughout the polyp and did not appear to alter or disrupt the overall configuration of its architecture, an observation that was also made by Pulitzer et al.[18] The largest focus was approximately 3 mm in diameter. The most interesting phenomenon was that these nests appeared to be *budding* directly from the base of the crypts where the adjacent adenomatous epithelium appeared to have undertaken similar histologic differentiation, as it had abundant eosinophilic cytoplasm, very similar to the cells described above. In the Figure (photomicrograph C), we capture this smooth transition from the usual adenomatous epithelium to adenomatous epithelium with more abundant eosinophilic cytoplasm and finally to the nests of endocrine cells that superficially infiltrate the muscularis propria. The ascending colon polyp was a regular tubular adenoma with no unusual features.

Immunohistochemistry

The microcarcinoid component stained positively with synaptophysin and neuron-specific enolase and negatively with chromogranin. Interestingly, an identical pattern of staining was evident in the adjacent adenomatous epithelium with abundant eosinophilic cytoplasm.

Follow-up

The patient underwent a follow-up colonoscopy a year later that revealed two more polyps in the large intestine, both of which were tubular adenomas with no unusual features.

DISCUSSION

Two hypotheses discuss the origin of mixed endocrine-exocrine tumors. In the first hypothesis, these lesions could be understood as two distinct tumors derived from two different precursors that coincidentally arise in the same location. This hypothesis could account for the histogenesis of collision-type tumors that are by definition excluded from the mixed tumor category. The second hypothesis postulates a monoclonal origin for the tumors: the two components may arise from a pluripotent epithelial stem cell capable of bidirectional differentiation.[2] In this section, we discuss several origin-related issues, including the embryologic monoderivation of epithelial and endocrine cells in the GI tract, the close relationship between glandular tumors and endocrine cells, and the genetic/molecular studies of these tumors. Last, we attempt to correlate these aspects with the findings of our case.

Since the beginning of the 20th century, the origin of gut endocrine cells has been controversial. There were two competing theories. The first postulated that gut endocrine cells are endodermally derived like the rest of the GI epithelial cells.[5] The second theory accounted for the cytochemical and ultrastructural similarities between these cells and other extra-GI endocrine cells (eg, parafollicular thyroid cells). All endocrine cells that display these features within and outside the GI tract were designated collectively as amine precursor uptake and decarboxylation cells, and the neural crest was thought to be a possible origin.[19]

In 1990, Thompson et al found that endocrine cells have the same clonal origin as other gut cell lineages, using an in situ DNA hybridization technique in chimeric mice.[6] Today, it is widely accepted that GI endocrine cells share the endodermal stem cell pool with other epithelial cells of this tract.[20,21] This finding is relevant because it provides strong evidence that the stem cells that give rise to the GI tract epithelial cells also give rise to the endocrine cells within it. Therefore, these cells are capable of dual differentiation toward endocrine and exocrine phenotypes.

The association between endocrine and exocrine cells goes beyond sharing a common progenitor. Several studies have shown the frequent presence of endocrine cells in colorectal adenomas, ranging from 59%-76%.[22,23] These cells were so numerous in some adenomas that they were regarded as an intrinsic part of the tumor.[23] Adenomas are monoclonal proliferations,[24] and the presence of endocrine cells within them is a clue that their precursor clone is capable of differentiation toward the endocrine phenotype while giving rise to adenomatous exocrine cells.

The ability of a clone to differentiate into both endocrine and exocrine phenotypes is suggestive of a monoclonal origin for mixed neoplasms; however, this differentiation ability is not considered sufficient evidence of a monoclonal origin. Several studies have investigated this theory at the molecular and genetic level. Furlan et al studied five mixed endocrine-exocrine neoplasms and one collision tumor using allelotyping analysis, a technique that offers valuable information when studying a lesion that has components with different histologic phenotypes or grades.[2] Allelotyping analysis detects consistently prevalent

genetic alterations that are considered an early event in tumorigenesis, regardless of the histologic phenotype. This high prevalence implies that a precursor cell underwent these changes and that every component that displays them must have risen from this precursor (monoclonal origin). According to this model, additional genetic alterations restricted to specific histologic phenotypes are interpreted as events occurring later in the progression of the tumor. The same principle can be applied to tumors with one histologic phenotype but different grades of differentiation.

Furlan et al found that the endocrine and exocrine components in all five mixed neoplasms exhibited common genetic alterations, supporting the monoclonal theory. In addition, the endocrine component exhibited secondary alterations that were not present in the exocrine component and thus represented a later event. Therefore, the authors concluded that differentiation may occur from an exocrine to endocrine direction but not vice versa. Furlan et al also noted that in some cases the endocrine component was present in association with a minimal component of adenoma, suggesting that differentiation into an endocrine phenotype may have occurred at an early stage. The collision tumor in their study had different endocrine and exocrine genetics, suggesting a biclonal precursor.[2] Similar findings were demonstrated by other investigators using different methods.[25,26]

In our case, small groups of endocrine cells were seen *budding* from the crypts of the larger adenomatous (exocrine) component, distinguishing the tumor from collision tumors and also suggesting that endocrine cells were differentiating from exocrine cells and not vice versa. Furthermore, this lesion was still in its early stage; it mainly consisted of a small adenoma without high-grade dysplasia and had a microcarcinoid component. Although our report is limited by its single case size, as well as the lack of molecular confirmation to detect consistent, prevalent genetic alterations, we believe that this case may represent a very early precursor of a mixed endocrine-exocrine tumor that has not been described before. In addition, our case correlates with previous findings about this group of neoplasms. If such tumors remain untreated, the adenoma component may evolve into an invasive adenocarcinoma, and the microcarcinoid component may turn into a well-differentiated endocrine neoplasm (carcinoid vs malignant carcinoid). The lesion would meet the criteria for a mixed endocrine-exocrine tumor once the microcarcinoid component comprises one-third of the tumor bulk. If adenocarcinoma arises, it may completely destroy the adjacent endocrine component, especially if this component is in its early stages. Interestingly, grade progression from well-differentiated to poorly differentiated is very rare in endocrine tumors.[27]

In our opinion, the incidence of mixed endocrine-exocrine neoplasms could be more frequent than reported. Underreporting may be attributed to several reasons. For example, an early small endocrine component may be overlooked (Figure, photomicrograph A) or misinterpreted as squamous metaplasia or microinvasion.[18] Moreover, such a component may be destroyed by locally growing adenocarcinoma as hypothesized above, or an adenomatous component may be destroyed by locally growing poorly differentiated endocrine carcinoma. The end result in both scenarios would be a tumor with one histologic type, leaving no evidence that it arose as a mixed neoplasm.

CONCLUSION

In this case report, we provide histologic and immunohistochemical evidence to describe a mixed endocrine and exocrine tumor of the colon with an early precursor form.

REFERENCES

1. Capella C, La Rosa S, Uccella S, Billo P, Cornaggia M. Mixed endocrine-exocrine tumors of the gastrointestinal tract. *Semin Diagn Pathol*. 2000 May;17(2):91-103.
2. Furlan D, Cerutti R, Genasetti A, et al. Microallelotyping defines the monoclonal or the polyclonal origin of mixed and collision endocrine-exocrine tumors of the gut. *Lab Invest*. 2003 Jul;83(7): 963-971.
3. Pecorella I, Memeo L, Ciardi A, Rotterdam H. An unusual case of colonic mixed adenoendocrine carcinoma: collision versus composite tumor. A case report and review of the literature. *Ann Diagn Pathol*. 2007 Aug;11(4):285-290.
4. Doğan L, Karaman N, Bozdoğan N, Atalay C, Yilmaz KB. A case report of composite adenoendocrine carcinoma of the cecum: clinical and pathological evaluation. *Turk J Gastroenterol*. 2009 Jun;20(2):153-154.
5. Masson P. Carcinoids (argentaffin-cell tumors) and nerve hyperplasia of the appendicular mucosa. *Am J Pathol*. 1928 May; 4(3):181-212.
6. Thompson M, Fleming KA, Evans DJ, Fundele R, Surani MA, Wright NA. Gastric endocrine cells share a clonal origin with other gut cell lineages. *Development*. 1990 Oct;110(2):477-481.
7. Klöppel G, Perren A, Heitz PU. The gastroenteropancreatic neuroendocrine cell system and its tumors: the WHO classification. *Ann N Y Acad Sci*. 2004 Apr;1014:13-27.
8. Varghese NM, Zaitoun AM, Thomas SM, Senapati A, Theodossi A. Composite glandular-carcinoid tumour of the terminal ileum. *J Clin Pathol*. 1994 May;47(5):427-429.
9. Ulich TR, Kollin M, Lewin KJ. Composite gastric carcinoma. Report of a tumor of the carcinoma-carcinoid spectrum. *Arch Pathol Lab Med*. 1988 Jan;112(1):91-93.

10. Cary NR, Barron DJ, McGoldrick JP, Wells FC. Combined oesophageal adenocarcinoma and carcinoid in Barrett's oesophagitis: potential role of enterochromaffin-like cells in oesophageal malignancy. *Thorax*. 1993 Apr;48(4): 404-405.
11. Jiao YF, Nakamura S, Arai T, et al. Adenoma, adenocarcinoma and mixed carcinoid-adenocarcinoma arising in a small lesion of the colon. *Pathol Int*. 2003 Jul;53(7):457-462.
12. Moyana TN, Qizilbash AH, Murphy F. Composite glandular-carcinoid tumors of the colon and rectum. Report of two cases. *Am J Surg Pathol*. 1988 Aug;12(8):607-611.
13. Mori K, Shinya H, Kalisman M. A composite tumor in tubulovillous adenoma of the rectum. *Dis Colon Rectum*. 1978 Oct;21(7):506-509.
14. Kuang-I F, Sano Y, Kon H, Ikematsu H, Kaji Y, Fujimori T. A composite adenoma and carcinoid tumor in a single rectal polyp. *Endoscopy*. 2006;38 Suppl 2:E62.
15. Anagnostopoulos GK, Arvanitidis D, Sakorafas G, et al. Combined carcinoid-adenocarcinoma tumour of the anal canal. *Scand J Gastroenterol*. 2004 Feb;39(2):198-200.
16. Adhikari D, Conte C, Eskreis D, Urmacher C, Ellen K. Combined adenocarcinoma and carcinoid tumor in atrophic gastritis. *Ann Clin Lab Sci*. 2002 Fall;32(4):422-427.
17. July LV, Northcott KA, Yoshida EM, Carr DM, Owen DA. Coexisting carcinoid tumors in familial adenomatous polyposis-associated upper intestinal adenomas. *Am J Gastroenterol*. 1999 Apr;94(4):1091-1094.
18. Pulitzer M, Xu R, Suriawinata AA, Waye JD, Harpaz N. Microcarcinoids in large intestinal adenomas. *Am J Surg Pathol*. 2006 Dec;30(12):1531-1536.
19. Pearse AG, Polak JM. Neural crest origin of the endocrine polypeptide (APUD) cells of the gastrointestinal tract and pancreas. *Gut*. 1971 Oct;12(10):783-788.
20. Rawdon BB, Andrew A. Origin and differentiation of gut endocrine cells. *Histol Histopathol*. 1993 Jul;8(3):567-580.
21. Andrew A, Kramer B, Rawdon BB. The origin of gut and pancreatic neuroendocrine (APUD) cells—the last word? *J Pathol*. 1998 Oct;186(2):117-118.
22. Iwashita A, Watanabe H, Enjoji M. Argyrophil and argentaffin cells in adenomas of the colon and rectum. *Fukuoka Igaku Zasshi*. 1989 Feb;80(2):114-124.
23. Van den Ingh HF, Van den Broek LJ, Verhofstad AA, Bosman FT. Neuroendocrine cells in colorectal adenomas. *J Pathol*. 1986 Mar;148(3):231-237.
24. Fearon ER, Hamilton SR, Vogelstein B. Clonal analysis of human colorectal tumors. *Science*. 1987 Oct 9;238(4824):193-197.
25. Kim KM, Kim MJ, Cho BK, Choi SW, Rhyu MG. Genetic evidence for the multi-step progression of mixed glandular-neuroendocrine gastric carcinomas. *Virchows Arch*. 2002 Jan;440(1):85-93.
26. Vortmeyer AO, Lubensky IA, Merino MJ, et al. Concordance of genetic alterations in poorly differentiated colorectal neuroendocrine carcinomas and associated adenocarcinomas. *J Natl Cancer Inst*. 1997 Oct 1;89(19):1448-1453.
27. Tang LH, Shia J, Vakiani E, Dhall D, Klimstra DS. High grade transformation of differentiated neuroendocrine neoplasms (NENs) of the enteropancreatic system: a unique entity distinct from de novo high grade neuroendocrine carcinoma (HGNECa) in pathogenesis and clinical behavior [abstract 622]. 97th Annual Meeting. United States and Canadian Academy of Pathology. Denver, CO. March 1-7, 2008. *Lab Invest*. 2008 Jan;88(Suppl 1): 137A.

This article meets the Accreditation Council for Graduate Medical Education and the American Board of Medical Specialties Maintenance of Certification competencies for Patient Care and Medical Knowledge.