

Laminoplasty for Cervical Spinal Cord Stimulator Implantation in Patients With Cervical Spondylosis and Fusion: A Technical Note

Daniel J. Denis, MD,^{1,2} Tianyi Niu, MD,³ Pierre-Olivier Champagne, MD,⁴ Daniel C. Lu, MD³

¹Department of Neurosurgery, Ochsner Clinic Foundation, New Orleans, LA ²The University of Queensland Faculty of Medicine, Ochsner Clinical School, New Orleans, LA ³Department of Neurosurgery, University of California, Los Angeles, CA ⁴Department of Neurosurgery, University of Montreal Medical Center, Montreal, Quebec

Background: Epidural spinal cord stimulator (SCS) implantation is a commonly used strategy for treating refractory neuropathic pain, but the literature on the technical aspects of cervical SCS surgery remains scarce. Degenerative cervical stenosis and prior fusion surgery are relatively frequent conditions in this population, and the optimal method for cervical lead placement among such patients has not been established. Decompressive laminectomy may be required for cervical SCS placement in the presence of spinal stenosis. However, extensive decompression may increase the rate of lead migration and destabilize the spine, especially when performed above an existing fusion.

Case Series: We present a surgical technique for cervical SCS implantation and the cases of 3 patients with significant spinal stenosis and/or prior fusion. In these patients, the paddle lead placement was safely achieved using cervical laminoplasty techniques.

Conclusion: In addition to stabilizing the epidural paddle lead, laminoplasty offers several potential advantages compared to decompression alone.

Keywords: Cervical vertebrae, laminoplasty, neuropathic pain, spinal cord stimulation, spinal stenosis, spondylosis

Address correspondence to Daniel J. Denis, MD, Department of Neurosurgery, Ochsner Clinic Foundation, 1514 Jefferson Hwy., New Orleans, LA 70121. Tel: (310) 606-1403. Email: daniel.denis@ochsner.org

INTRODUCTION

Epidural spinal cord stimulator (SCS) implantation is a well-established treatment for refractory neuropathic pain.¹ Depending on the pain region that needs to be covered, electrodes can be placed in the thoracic spine (lower back and/or lower extremity pain) or in the cervical spine (occiput, neck, and/or upper extremity pain).²

Cervical SCS implantation is less commonly performed than thoracic SCS procedures and entails specific risks. The narrower size of the epidural space in the cervical spine and the small distance between the yellow ligament and the spinal cord (2–3 mm)³ can restrain lead placement and increases the risk of spinal cord injury, a limitation that is often made worse by concomitant spondylosis and stenosis of the cervical canal.⁴ Cervical laminectomy can be performed to decompress the spinal canal before paddle lead placement, but bone removal and the high mobility of the cervical spine are thought to contribute to the higher rate of postoperative lead migration.^{5–8} A significant proportion of patients considered for cervical SCS implantation might also have had previous cervical spine surgery.^{9,10} If the spine was previously fused, the levels adjacent to the fusion are prone to instability,¹¹ which can be hastened by laminectomy.¹²

The literature on technical aspects of cervical SCS implantation is scarce.^{7,8} Although degenerative cervical changes and surgery are relatively frequent conditions, the published literature does not provide the optimal method for cervical lead placement in patients with these conditions.

We report a surgical technique for placement of cervical epidural paddle leads and present the cases of 3 patients with significant spinal stenosis and/or previous fusion surgery.

SURGICAL TECHNIQUE

Patients were referred to our neurosurgery spine clinics for chronic intractable upper extremity neuropathic pain of a known, identifiable cause. Patients without any medical or psychological contraindications were selected for a percutaneous trial of the SCS. All patients had cervical magnetic resonance imaging (MRI) studies showing moderate to severe spinal stenosis prior to the percutaneous trial. Patients who had a successful pain response (>50% pain relief) during the trial were scheduled for implantation of a 32-channel Precision Spectra paddle electrode (Boston Scientific Corp.) or a 16-contact paddle electrode (Neuro Corp.).

The procedure is performed under general anesthesia and neurophysiologic monitoring, including motor evoked potentials, somatosensory evoked potentials, and electromyography. The patient is positioned prone on the surgical table with the head held in a slightly flexed position with the Mayfield clamp (Integra LifeSciences). The subaxial cervical spine that corresponds to the levels of stenosis down to the spinous process of C7 are accessed via a standard posterior midline approach with subperiosteal dissection of the paraspinal muscles to expose the spinal laminae. Dissection is carried out laterally with care to preserve the facet capsules.

Expansive cervical laminoplasty using the laminar roof reconstruction technique^{13,14} or the open door technique is then performed to allow safe and controlled placement of cervical epidural paddle leads in patients with concomitant spinal stenosis and/or risk of subsequent instability because of prior surgery.

For the roof reconstruction technique, the cervical laminae corresponding to each stenotic segment are cut bilaterally with a high-speed drill equipped with a 3 mm match head-shaped burr along the lateral spinal canal. The laminae, spinous processes, and associated ligaments are reflected inferiorly en bloc once the rostral supraspinous and interspinous ligaments are divided. The laminar roof can then be prepared for fixation with laminoplasty titanium miniplates and screws.

For the open door laminoplasty technique, a full thickness strut is performed on the ipsilateral side laminae, and a partial thickness strut is made on the other side to allow for a lateral opening of the laminae. The assistant keeps the open door laminoplasty open using two curved curettes. The epidural space is dissected with a Woodson elevator, and the paddle lead is placed at the desired level. Adequate coverage and lateralization can be obtained based on electromyographic responses from the electrode pairs stimulated.

The laminae are lowered onto the paddle lead and fixed unilaterally with laminoplasty titanium miniplates and screws. Using loupes or microscopic magnification can be useful to correctly screw the miniplates. The height of the laminoplasty can be controlled to achieve optimal paddle lead placement over the dura. Early migration can be avoided if the paddle lead is gently snugged between the dura and the laminar roof. Several strain-relief loops of the lead tails are placed under the subfascial muscles, and the distal tails are secured with a 0 silk suture at the interspinous ligament. The pulse generator is placed in the right or left flank, and a subcutaneous tunneling device is used to pass a connecting wire from the pulse generator to the electrode. The subfascial muscles are reapproximated, and the cervical fascial layers are tightly closed.

CASE SERIES

Patient 1

A 62-year-old male with a history of right hypertensive thalamus hemorrhage 7 years prior presented with left upper and lower extremity neuropathic central pain. Average visual analog scale (VAS) score was 6/10. The pain was intractable to numerous medications, including opioids and gabapentin. Preoperative cervical spine MRI demonstrated moderate C5-C6 and C6-C7 spinal stenosis (Figure 1A, top image). Although thalamic pain is an uncommon indication for SCS treatment, limb pain caused by chronic regional pain syn-

drome or after brachial plexus injury is a well-established indication for SCS implantation.^{1,2} The patient underwent percutaneous placement of epidural electrodes as part of an SCS trial without perioperative complication. His left arm pain resolved by approximately 75%, and discontinuation of the stimulation led to pain recurrence. Permanent epidural paddle lead placement was then performed at C5-C7 through a C6-C7 roof reconstruction laminoplasty. No complications were encountered, and the patient's recovery was unremarkable. He was discharged from the hospital on postoperative day 2, and his SCS was turned on the day after the surgery. The patient reported persistent improvement in his left upper extremity pain at 6-month follow-up, and cervical x-rays revealed satisfactory paddle lead placement without evidence of lead migration (Figure 1A, middle and bottom images). At his 16-month follow-up, the patient was still responsive to the SCS.

Patient 2

A 62-year-old male with a history of C4-C7 anterior cervical discectomy and fusion, posterior left C6-C7 foraminotomy, and left ulnar nerve release surgery presented with left upper extremity neurogenic pain in the distribution of C6 that had been worsening for the prior 2 years. The pain became refractory to medication and was scored at 6/10 on the VAS. Neurologic examination revealed normal strength bilaterally except for shoulder abduction (3/5) on the right side as a result of prior injury and no sign of myelopathy. MRI of the cervical spine revealed no neurologic compromise to explain the pain (Figure 1B, top image). The cause of the pain was believed to be iatrogenic secondary to nerve injury from one of the previous surgeries. The patient underwent a cervical SCS trial that provided >75% pain relief. Following the patient's positive response to the trial, definitive surgery was planned. Laminoplasty was preferred for this case because the access would require opening beyond a surgically fused region that could destabilize the spine. The patient underwent a left C3-C5 open door laminoplasty and C2 laminotomy for the insertion of an epidural paddle lead from C2-C5. His postoperative course was uneventful. Postoperative cervical spine x-rays confirmed good positioning of the lead (Figure 1B, middle and bottom images), and at 3-month follow-up, the patient reported complete resolution of left upper extremity pain.

Patient 3

A 59-year-old male presented with refractory bilateral upper extremity neurogenic pain (worse on the right side) following central cord syndrome. The initial injury came from a C5-C6 traumatic disc herniation causing severe spinal stenosis. A C5-C6 anterior cervical discectomy and fusion were performed. Four months after the cervical fusion, neurologic examination revealed allodynia of both upper extremities, weakness (4/5) of the left interossei muscles, diminished dexterity in both hands, and gait imbalance. Cervical spine MRI showed no new neural structure compromise (Figure 1C, top image). The patient underwent a cervical SCS trial that provided >70% pain relief. Following the positive results of the trial, the patient underwent a right C3-C5 open door laminoplasty and placement of a right-sided epidural paddle lead from C3-C5. Laminoplasty was favored in this case because of previous fusion of the

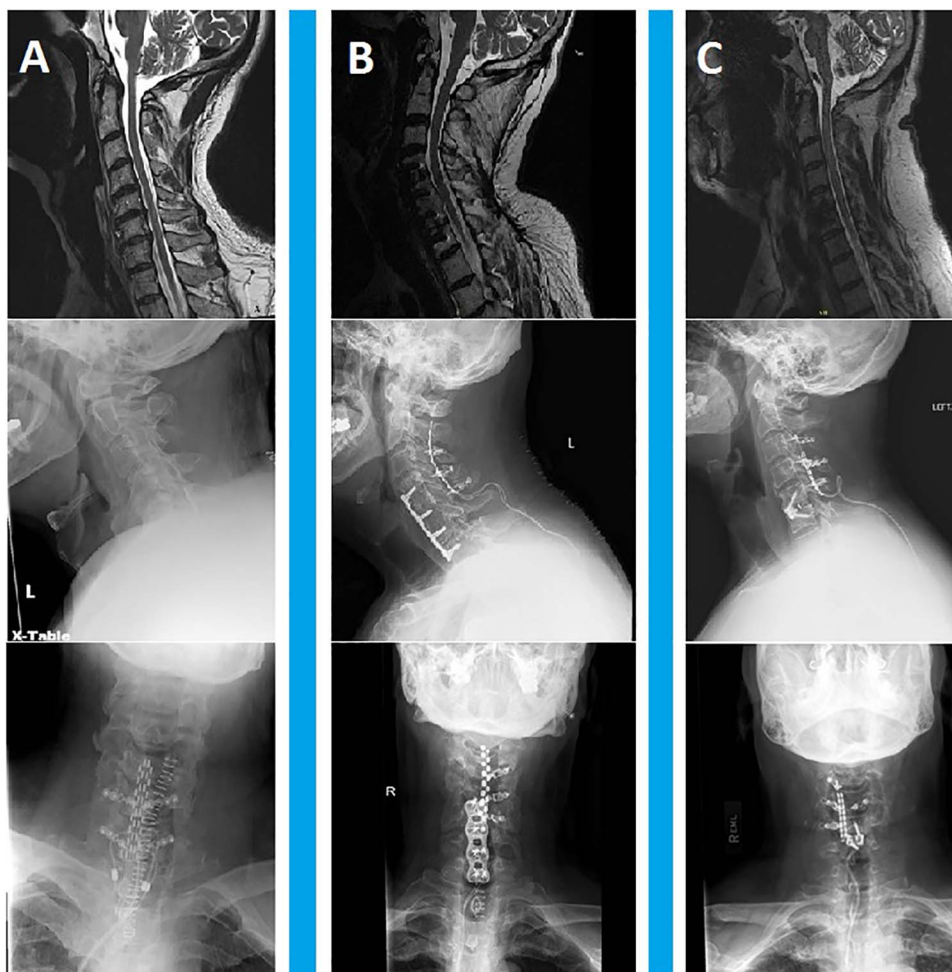


Figure 1. Preoperative and postoperative imaging of the 3 cases. A. Imaging of patient 1. Preoperative (top image) sagittal T2-weighted magnetic resonance imaging (MRI) shows cervical stenosis, and early postoperative (middle image) anteroposterior and (bottom image) lateral x-rays show the instrumentation of laminoplasty and good placement of the paddle lead. B. Imaging of patient 2. Preoperative (top image) sagittal T2-weighted MRI shows good alignment of the spine and previous anterior fusion from C4-C7, and early postoperative (middle image) anteroposterior and (bottom image) lateral x-rays show the instrumentation of laminoplasty and good placement of the paddle lead. C. Imaging of patient 3. Preoperative (top image) sagittal T2-weighted MRI shows good alignment of the spine and previous anterior fusion at C5-C6, and early postoperative (middle image) anteroposterior and (bottom image) lateral x-rays show the instrumentation of laminoplasty and good placement of the paddle lead.

spine. The patient's postoperative course was uneventful. Postoperative cervical spine x-rays confirmed good positioning of the lead (Figure 1C, middle and bottom images), and follow-up at 4 months revealed resolution of the right-sided pain.

DISCUSSION

Epidural SCS placement in patients with cervical stenosis is particularly challenging because the already narrow space between the cervical spinal cord and yellow ligament is further limited, and forceful lead insertion may increase the risk of spinal cord injury and myelopathy.¹⁵ Progression of cervical spondylosis and stenosis may also predispose

patients with a cervical SCS to develop spinal cord injury from the paddle lead.⁴ Decompressing the spinal cord with a traditional laminectomy offers safe placement of the paddle lead but has the potential for long-term segmental instability and kyphotic deformity in 15%-43% of cases.¹⁶ In addition, laminectomy has the potential to increase the risk of postoperative lead displacement because the bone that stabilizes the paddle lead in the epidural space has been removed. The significant mobility of the cervical spine contributes to higher rates of postoperative migration and breakage compared to the thoracic SCS, leading to long-term failure and revision rates of 22%-50% reported in large published series.^{1,5-7,17}

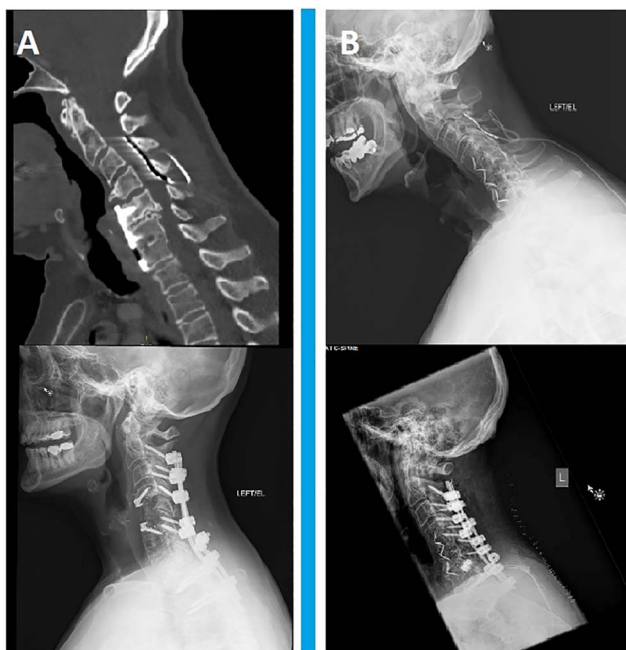

Figure 2. Illustrative cases of spinal instability after paddle lead placement in patients with prior cervical fusion. **A.** Sagittal computed tomography scan (bone window) of the cervical spine shows loss of alignment above the fused levels (top image). The patient presented with progressive myelopathy secondary to worsening cord compression 6 months after paddle lead placement. Lateral cervical x-ray shows posterior fusion surgery required for the case (bottom image). **B.** Lateral x-ray of the cervical spine shows loss of alignment above the fused levels (top image). The patient presented 9 months after paddle lead placement with worsening neck pain and myelopathy secondary to instability. Lateral cervical x-ray shows posterior fusion surgery required for the case (bottom image).

Although cervical laminoplasty has been associated with prolonged neck pain, loss of range of motion, and worsening cervical kyphosis,¹⁸ preserving the supraspinous and interspinous ligaments at the distal ends of the laminoplasty may provide more stability than laminectomy.¹⁶ The two laminoplasty techniques described provide a means to stabilize the lead paddle in the epidural space.¹³ In addition, preservation of the lamina has been shown to reduce scar tissue formation.¹⁹ Scar tissue following laminotomy for SCS implantation is associated with loss of stimulation effect caused by early migration,^{6,20} and more rarely, development of myelopathy.²¹

Another situation in which we believe laminoplasty could benefit SCS placement is in patients with prior neck fusion surgery. Posterior elements resection above the site of prior fusion can lead to instability and deformity. Figure 2 shows imaging for 2 patients who presented with progression of kyphosis, neck pain, and myelopathy following SCS placement through a laminotomy involving disruption of the supraspinous and interspinous ligaments just above the site of a prior fusion surgery. These patients were treated with posterior cervical laminectomy and cervicothoracic fusion, resulting in complete resolution of their neck

pain at 3-month follow-up. In one patient, the SCS was removed. In the second patient, the paddle lead was repositioned higher at C2-C3, but the patient did not use the SCS because of the absence of neck and arm pain after the surgery. We believe the disruption of the posterior elements at the site of the laminotomy contributed to the instability and subsequent deformity in these 2 patients. Randomized studies and longer follow-up are needed to confirm that laminoplasty is superior to laminectomy in preventing progressive kyphosis and to determine if the rates of lead displacement and revision differ based on the type of decompression performed.

CONCLUSION

We believe that laminoplasty is a safe alternative to laminectomy in patients with significant degenerative spinal stenosis and in patients who have had prior fusion surgery. While laminoplasty for SCS paddle placement may decrease lead migration and the rate of deformity progression by preserving the posterior structures, further studies are needed to address long-term outcomes.

ACKNOWLEDGMENTS

The authors have no financial or proprietary interest in the subject matter of this article.

REFERENCES

1. Kumar K, Nath R, Wyant GM. Treatment of chronic pain by epidural spinal cord stimulation: a 10-year experience. *J Neurosurg.* 1991;75(3):402-407. doi: 10.3171/jns.1991.75.3.0402.
2. Song JJ, Popescu A, Bell RL. Present and potential use of spinal cord stimulation to control chronic pain. *Pain Physician.* 2014 May-Jun;17(3):235-246.
3. Zhao Q, Huang K, An J, et al. The distance from skin to cervical and high thoracic epidural space on Chinese adults as read from MRI. *Pain Physician.* 2014 Mar-Apr;17(2):163-168.
4. Falowski S, Ooi YC, Sabesan A, Sharan A. Spinal cord injury induced by a cervical spinal cord stimulator. *Neuromodulation.* 2011 Jan;14(1):34-36; discussion 36-37. doi: 10.1111/j.1525-1403.2010.00313.x.
5. Simpson BA, Bassett G, Davies K, Herbert C, Pierri M. Cervical spinal cord stimulation for pain: a report on 41 patients. *Neuromodulation.* 2003 Jan;6(1):20-26. doi: 10.1046/j.1525-1403.2003.03003.x.
6. Rosenow JM, Stanton-Hicks M, Rezai AR, Henderson JM. Failure modes of spinal cord stimulation hardware. *J Neurosurg Spine.* 2006 Sept;5(3):183-190. doi: 10.3171/spi.2006.5.3.183.
7. Amrani J. A novel technique for the implantation of paddle leads in the cervical spine. *Neuromodulation.* 2013;16(6):546-550; discussion 550. doi: 10.1111/ner.12022.
8. Pahapill PA. A novel nonanchoring technique for implantation of paddle leads in the cervical spine under conscious sedation. *Neuromodulation.* 2015 Aug;18(6):472-476; discussion 476-477. doi: 10.1111/ner.12283.
9. Deer TR, Skaribas IM, Haider N, et al. Effectiveness of cervical spinal cord stimulation for the management of chronic pain. *Neuromodulation.* 2014 Apr;17(3):265-271; discussion 271. doi: 10.1111/ner.12119.
10. Chivukula S, Tomycz ND, Moossy JJ. Paddle lead cervical spinal cord stimulation for failed neck surgery syndrome. *Clin Neurol Neurosurg.* 2013 Oct;115(10):2254-2256. doi: 10.1016/j.clineuro.2013.07.002.

11. Kienapfel H, Koller M, Hinder D, et al. Integrated outcome assessment after anterior cervical discectomy and fusion: myelocompression but not adjacent instability affect patient-reported quality of life and cervical spine symptoms. *Spine*. 2004 Nov 15;29(22):2501-2509.
12. Deutsch H, Haid RW, Rodts GE, Mummaneni PV. Postlaminectomy cervical deformity. *Neurosurg Focus*. 2003 Sep;15(3):E5.
13. Wiedemayer H, Sandalcioglu IE, Aalders M, Wiedemayer H, Floerke M, Stolke D. Reconstruction of the laminar roof with miniplates for a posterior approach in intraspinal surgery: technical considerations and critical evaluation of follow-up results. *Spine*. 2004 Aug 15;29(16):E333-E342.
14. Asgari S, Bassiouni H, Massoud N, Schlamann M, Stolke D, Sandalcioglu IE. Decompressive laminoplasty in multisegmental cervical spondylotic myelopathy: bilateral cutting versus open-door technique. *Acta Neurochir (Wien)*. 2009 Jul;151(7):739-749; discussion 749. doi: 10.1007/s00701-009-0343-0.
15. Meyer SC, Swartz K, Johnson JP. Quadriplegia and spinal cord stimulation: case report. *Spine (Phila Pa 1976)*. 2007 Sep 1;32(19):E565-E568. doi: 10.1097/BRS.0b013e31814541dc.
16. Healy AT, Lubelski D, West JL, Mageswaran P, Colbrunn R, Mroz TE. Biomechanics of open-door laminoplasty with and without preservation of posterior structures. *J Neurosurg Spine*. 2016 May;24(5):746-751. doi: 10.3171/2015.7.SPINE15229.
17. Quigley DG, Arnold J, Eldridge PR, et al. Long-term outcome of spinal cord stimulation and hardware complications. *Stereotact Funct Neurosurg*. 2003;81(1-4):50-56. doi: 10.1159/000075104.
18. Cho SK, Kim JS, Overley SC, Merrill RK. Cervical laminoplasty: indications, surgical considerations, and clinical outcomes. *J Am Acad Orthop Surg*. 2018 Apr 1;26(7):e142-e152. doi: 10.5435/JAAOS-D-16-00242.
19. Yucesoy K, Karci A, Kilicalp A, Mertol T. The barrier effect of laminae: laminotomy versus laminectomy. *Spinal Cord*. 2000;38(7):442-444.
20. Kim DD, Vakharya R, Kroll HR, Shuster A. Rates of lead migration and stimulation loss in spinal cord stimulation: a retrospective comparison of laminotomy versus percutaneous implantation. *Pain Physician*. 2011 Nov-Dec;14(6):513-524.
21. Wloch A, Capelle HH, Saryyeva A, Krauss JK. Cervical myelopathy due to an epidural cervical mass after chronic cervical spinal cord stimulation. *Stereotact Funct Neurosurg*. 2013;91(4):265-269. doi: 10.1159/000346501.

This article meets the Accreditation Council for Graduate Medical Education and the American Board of Medical Specialties Maintenance of Certification competencies for Patient Care and Medical Knowledge.