

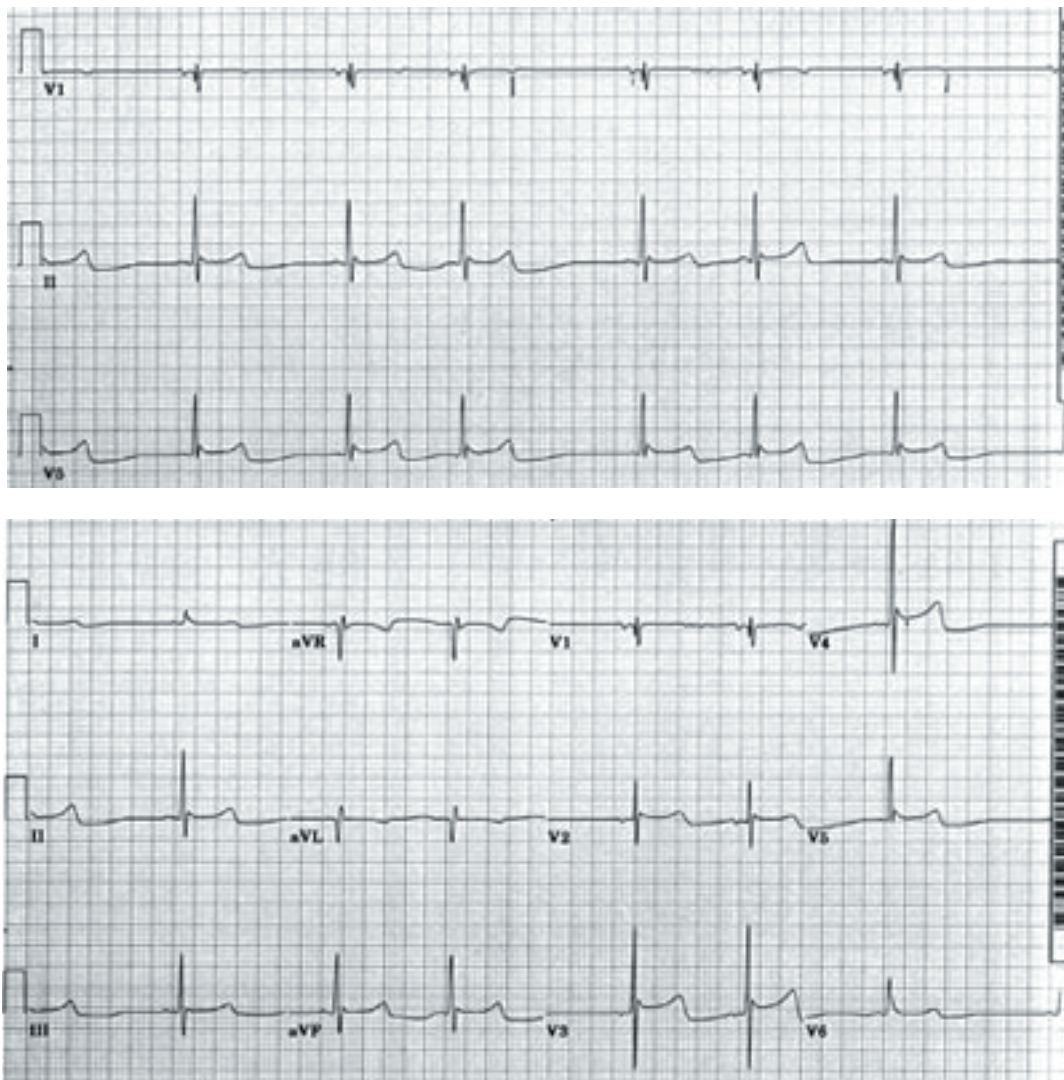
Ochsner Medical Case Study

Presentation

An 85-year-old homeless male was brought in by the EMS in an unresponsive state. An EKG recorded in the Emergency Department is shown in the figures.

Questions

1. What is your diagnosis?
2. What is the diagnostic EKG sign called?
3. List the EKG changes commonly seen in this condition.
4. Name some other conditions where these EKG changes are seen.



Answers on page 120.

This case study was prepared by Dr. Mohamed Khan, a fellow in Ochsner's Cardiology Department.
The Ochsner Journal's Medical Case Studies are edited by Dr. Hector Ventura.

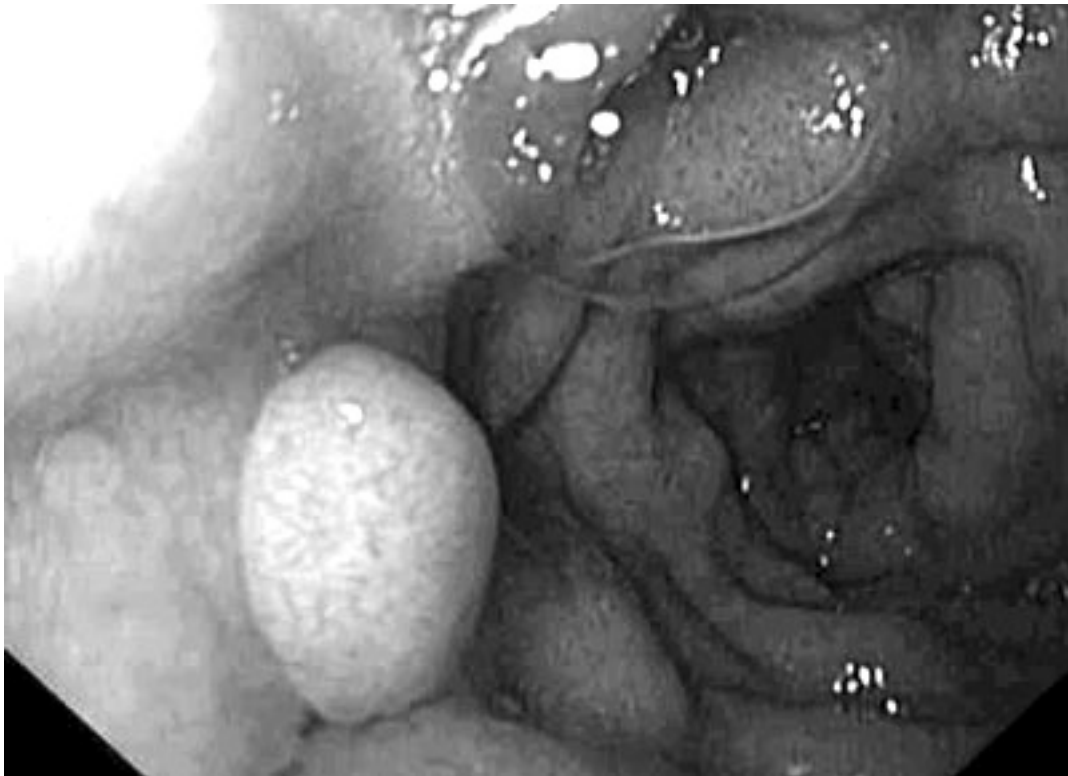Ochsner Surgical Case Study

Presentation

A 48-year-old black female with a history of familial adenomatous polyposis (FAP) was evaluated by the Ochsner general surgery service with duodenal polyposis. She had a history of bleeding from the polyps intermittently but was otherwise asymptomatic. She had undergone resection of an abdominal wall desmoid tumor as well as duodenotomy with periampullary polyp removal. She had been followed on an annual basis with upper endoscopy. She had undergone total proctocolectomy with ileostomy creation in the 1970s for her FAP. Her father had also been diagnosed with FAP and had a total proctocolectomy. She has no other significant medical or surgery history.

Questions

1. What is the diagnosis?
2. What therapy is indicated for this patient?



Answers on page 120.

This case study was prepared by Dr. David H. Hayes, a fellow in Ochsner's Surgery Department.
The Ochsner Journal's Surgical Case Studies are edited by Dr. William Richardson.